

See discussions, stats, and author profiles for this publication at: <https://www.researchgate.net/publication/11388016>

# Nerve Entrapments of the Lower Leg, Ankle and Foot in Sport

Article in *Sports Medicine* · February 2002

DOI: 10.2165/00007256-200232060-00003 · Source: PubMed

CITATIONS

104

READS

31,484

3 authors, including:



**Paul McCrory**

The Florey Institute of Neuroscience and Mental Health

530 PUBLICATIONS 24,688 CITATIONS

[SEE PROFILE](#)

Some of the authors of this publication are also working on these related projects:



Long term follow up of athlete cohorts - international multi centre collaboration [View project](#)



Berlin Papers [View project](#)

# Nerve Entrapments of the Lower Leg, Ankle and Foot in Sport

Paul McCrory,<sup>1,2,3</sup> Simon Bell<sup>4</sup> and Chris Bradshaw<sup>2</sup>

- 1 Department of Neurology, Olympic Park Sports Medicine Centre, Melbourne, Victoria, Australia
- 2 Department of Sports Medicine, Olympic Park Sports Medicine Centre, Melbourne, Victoria, Australia
- 3 Centre for Sports Medicine Research and Education and Brain Research Institute, University of Melbourne, Parkville, Victoria, Australia
- 4 Department of Orthopaedics, Olympic Park Sports Medicine Centre, Melbourne, Victoria, Australia

## Contents

Abstract	372
1. Anatomical Features of Nerve Entrapment Syndromes	373
1.1 General Approach to Neurogenic Leg Pain	373
1.2 History	373
1.3 Key Symptoms	373
1.4 Examination	375
1.5 Investigations	375
2. Specific Nerve Entrapment Syndromes	375
2.1 Saphenous Nerve	375
2.1.1 Anatomy	375
2.1.2 Aetiology	375
2.1.3 Clinical Presentation	376
2.1.4 Investigation	376
2.1.5 Management	376
2.1.6 Surgical Management	376
2.2 Common Peroneal Nerve	377
2.2.1 Anatomy	377
2.2.2 Aetiology	377
2.2.3 Clinical Presentation	379
2.2.4 Investigations	380
2.2.5 Surgical Management	380
2.3 Sural Nerve	381
2.3.1 Anatomy	381
2.3.2 Aetiology	381
2.3.3 Clinical Presentation	381
2.3.4 Management	382
2.3.5 Surgical Management	383
2.4 Tibial Nerve	383
2.4.1 Anatomy	383
2.4.2 Aetiology	383
2.4.3 Clinical Presentation	385

2.4.4 Investigation . . . . .	385
2.4.5 Management . . . . .	385
2.4.6 Surgical Treatment of Tarsal Tunnel Syndrome . . . . .	386
2.5 Plantar Interdigital Nerves . . . . .	386
2.5.1 Anatomy . . . . .	386
3. Other Neurogenic Causes of Exercise-Related Lower Limb Symptoms . . . . .	387
3.1 Muscle Cramp Syndromes . . . . .	388
4. Overlap of Clinical Syndromes Causing Exercise-Related Leg Pain . . . . .	388
5. Conclusion . . . . .	389

## Abstract

Exercise-related leg pain is a common and yet difficult management problem in sports medicine. There are many common causes of such symptoms including stress fractures and muscle compartment syndromes. There are also a number of less common but important conditions including popliteal artery entrapment and nerve entrapment syndromes. Even for an astute clinician, distinction between the different medical causes may be difficult given that many of their presenting features overlap. This review highlights the common clinical presentations and raises a regional approach to the diagnosis of the neurogenic symptoms. In part, this overlapping presentation of different pathological conditions may be due to a common aetiological basis of many of these conditions namely, fascial dysfunction. The same fascial restriction that predisposes to muscle compartment syndromes may also envelop the neurovascular structures within the leg resulting in either ischaemic or neurogenic symptoms. For many athletes with chronic exercise-related leg pain, combinations of such problems often coexist suggesting a more widespread fascial pathology. In our clinical experience, we often label such patients as 'fasciopath's'; however, the precise pathophysiological basis of this fascial problem remains to be elucidated. This review discusses the various nerve entrapment syndromes in the lower limb that may result in exercise-related leg pain in the sporting context. The anatomy, clinical presentation, investigation, medical management and surgical treatment are discussed at length for each of the syndromes. It is clear from clinical experience that the outcome of surgical management of such syndromes fares much better where a clear dermatomal pain distribution is present or where focal weakness and/or sensory symptoms appropriate for the nerve are present. In many situations, however, nonspecific leg pain or vague nonlocalising sensory symptoms are present and in such situations, alternative diagnoses must be considered and investigated appropriately. As mentioned above, many different pathologies may coexist in the lower limb and may be a source of confusion for the clinician or alternatively may be the reason for poor treatment outcomes.

Exercise-related leg pain represents one of the most common presentations in sports medicine. This is usually caused by musculoskeletal overuse injuries, but not uncommonly, a neurogenic cause may be suspected. Because of the complex anatomy of the leg, few clinicians have a detailed un-

derstanding of all the potential neurological causes of such pain.<sup>[1-5]</sup> To complicate matters further, many of the clinical presentations overlap, in spite of the fact that the underlying pathophysiology may be related to separate vascular, compartment or neurological dysfunction. In this review, the rel-

evant neurological syndromes will be discussed along with their surgical management.

There are a variety of neurological causes for pain in this region apart from focal peripheral nerve entrapments. These include radicular pain arising from compression or irritation of the lumbosacral nerve roots, referred pain from innervated structures of the spine, polyneuropathies, myopathies and other forms of muscle disease as well as the various chronic regional pain syndromes. These will not be discussed further in this review.

## 1. Anatomical Features of Nerve Entrapment Syndromes

A summary of the nerves and their motor and sensory distribution where it relates to the leg is set out in table I. It must be emphasised that many nerve entrapment syndromes may present with nonspecific or poorly localised pain. Furthermore, the cutaneous dermatomal distribution is extremely variable between individuals (figure 1).

### 1.1 General Approach to Neurogenic Leg Pain

Unless nerve entrapment syndromes produce 'hard' neurological signs of motor weakness, sensory loss or change in tendon reflexes, specific diagnosis may be difficult and often circumstantial. For this reason, a regional approach to the likely nerve entrapments may be useful and then the ap-

propriate electrophysiological studies sought if the diagnostic suspicion is sufficient.<sup>[1]</sup>

### 1.2 History

The aim of the history in a patient with possible neurogenic leg pain is to determine the location and timing of the pain, its mechanism of onset, degree of irritability, aggravating and relieving factors, presence of other joint pain or swelling, previous local trauma and the presence of neurological signs or symptoms. The previous history of back pain and its response to treatment may be particularly important in diagnosis. An occupational and sporting history is similarly important in determining the aetiology of such syndromes.<sup>[6]</sup>

### 1.3 Key Symptoms

There are a number of important symptoms that should be specifically sought for as they may indicate the presence of potentially serious neurological disease unrelated to the focal nerve entrapments being discussed in this review. For example, spinal cord disease may be suggested by sphincter dysfunction, spinal root or radicular disease by the presence of focal weakness or dermatomal sensory disturbance, vascular obstruction by claudicant leg pain and occult malignancy by systemic symptoms. Night pain or rest pain is a particularly important symptom to assess since it may indicate inflammatory, malignant or infective causes of pain. Patients reporting such symptoms should be

**Table I.** Nerves of the lower leg

Nerve	Main branches in leg	Motor innervation in leg	Sensory distribution in leg
Femoral nerve	Saphenous nerve, infra-patellar nerve	Nil	Medial and anterior knee (infra-patellar branch) and medial leg, ankle and arch of foot (saphenous branch)
Common peroneal nerve	Superficial peroneal nerve, deep peroneal nerve, lateral cutaneous nerve of calf, sural communicating nerve	Peroneus longus and brevis, tibialis anterior, extensor hallucis longus, extensor digitorum longus, peroneus tertius, extensor digitorum brevis	Lateral calf, dorsum of foot, 1st web-space
Tibial nerve	Anterior tibial nerve, posterior tibial nerve, sural nerve	Gastrocnemius, soleus, tibialis posterior, flexor digitorum longus, flexor hallucis longus	Lateral aspect of ankle and foot (sural nerve)

immediately referred for neurological assessment.  
These include:

- Bladder or bowel dysfunction
- Focal or global weakness in the lower limbs

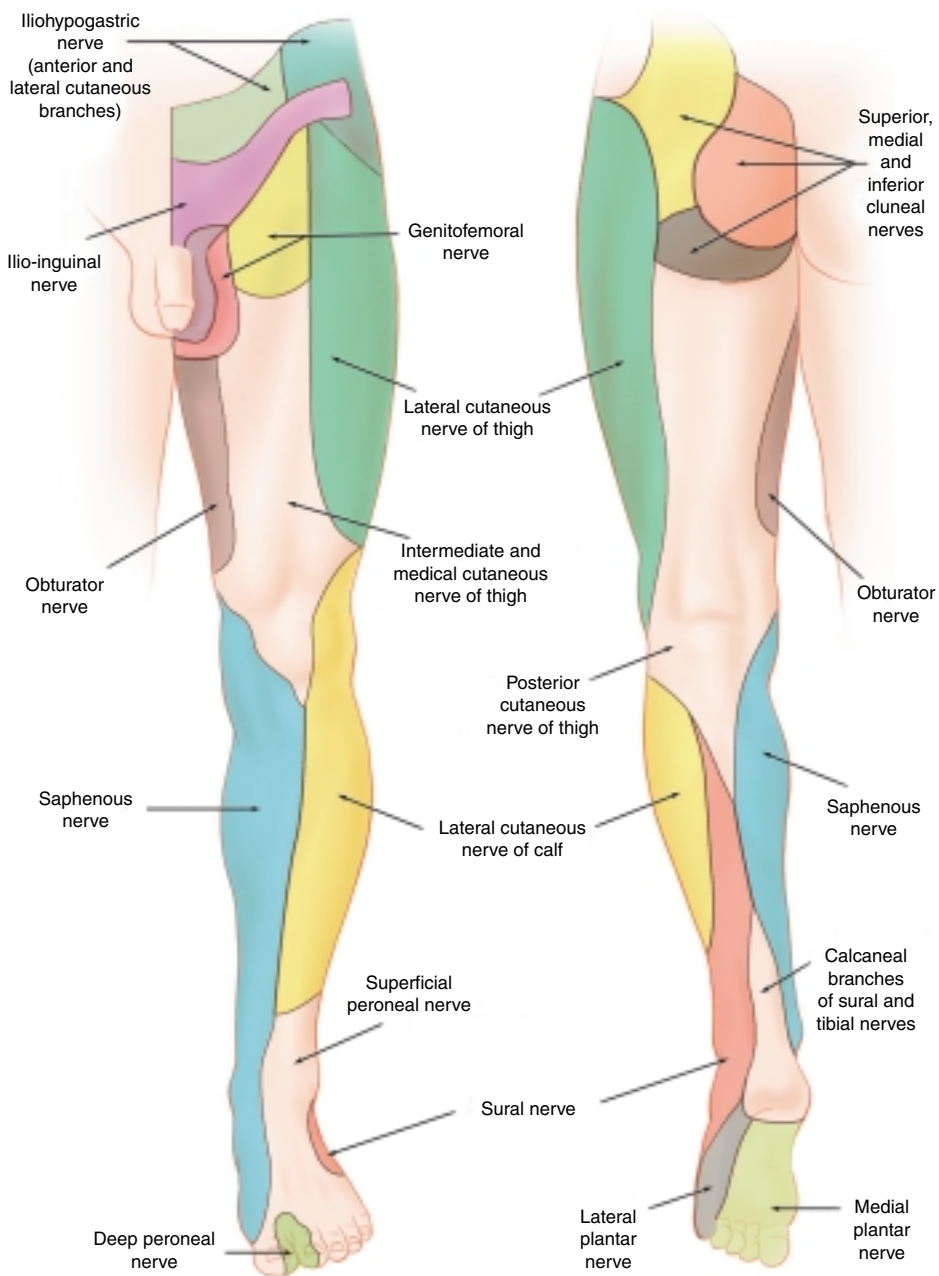


Fig. 1. Cutaneous innervation in the lower limb.

- Loss of sensation or ‘pins and needles’
- Loss of coordination in the lower limbs
- Systemic symptoms (e.g. fever, night sweats and loss of bodyweight)
- Night pain or rest pain
- Lower limb or buttock pain that gets worse with exercise
- Unilateral leg pain and swelling.

1.4 Examination

Details of neurological examination skills are beyond the scope of this article. Readers are referred to general neurological texts for further reading.<sup>[7]</sup>

1.5 Investigations

In the management of most cases of leg pain where a neurological diagnosis is suspected, specific confirmatory tests such as nerve conduction studies or electromyography should be sought.<sup>[8,9]</sup> The main role of radiological imaging modalities such as isotope bone scanning, ultrasound and magnetic resonance imaging (MRI) relate to the detection of bone and soft tissue lesions rather than neurological disease.<sup>[10,11]</sup>

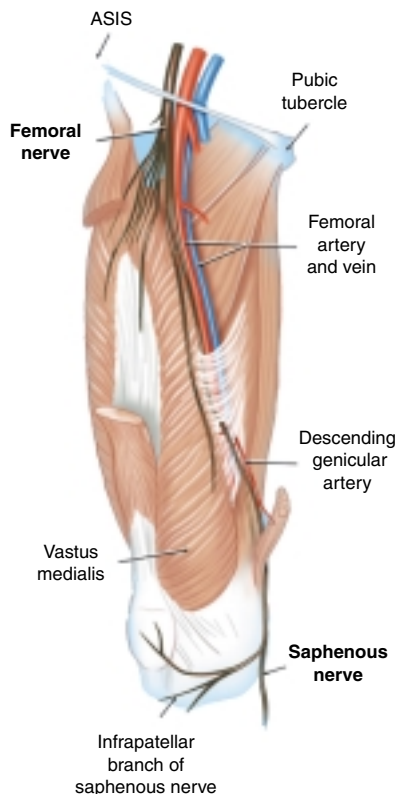
**2. Specific Nerve Entrapment Syndromes**

The various specific nerve entrapment syndromes are discussed separately. The list of references for each syndrome is not meant to be exhaustive and readers are referred to the general texts in the reference list for further information.<sup>[9,12]</sup>

2.1 Saphenous Nerve

**2.1.1 Anatomy**

This is the longest sensory branch of the femoral nerve arising from the L1,2,3 nerve roots. The nerve leaves the femoral triangle to enter the adductor canal (or subsartorial canal of Hunter) together with the femoral artery and vein. The walls of the canal comprise vastus medialis and adductor longus muscle and the roof is bridged by the vasto-adductor membrane. The sartorius muscle covers



**Fig. 2.** Anatomy of the femoral nerve and its distal branches. ASIS = anterior superior iliac spine.

the proximal portion of the canal and also covers the two terminal branches of the saphenous nerve, the infrapatellar branch and the descending branch<sup>[9,12]</sup> (figures 2 and 3).

The infra-patellar branch supplies the sensation to the medial portion of the joint and the overlying anteromedial skin. The descending branch accompanies the saphenous vein to supply the skin of the medial leg and foot (figure 2).

**2.1.2 Aetiology**

The nerve may be injured in the adductor canal by local trauma, surgery or inflammatory conditions such as thrombophlebitis. In the region of the knee, surgery is the principal cause where the nerve may be injured or irritated at the site of an

arthroscopic portal. Local injuries may similarly result in saphenous nerve symptoms either from

direct trauma or pes anserine bursitis, which may irritate the nerve. Some authors have speculated that stretching the nerve during knee flexion may be a biomechanical explanation of the aetiology of this condition especially where cases of saphenous nerve entrapment in bodybuilding have been reported.<sup>[13-17]</sup>

**2.1.3 Clinical Presentation**

The typical presentation is of **claudicant or exercise-related medial leg or knee pain**. This condition may be easily confused with vascular disorders such as popliteal artery entrapment. Compression or percussion (Tinel’s sign) of the nerve in the region of the adductor canal or where the nerve crosses the medial femoral condyle usually produces pain or ‘tingling’ radiating to the medial malleolus and occasionally more distally on the medial leg. Alteration of sensation in the cutaneous distribution of the nerve may be present.<sup>[18]</sup> In our experience, entrapment or injury to the infrapatellar branch produces a poorly localised anteromedial knee pain. Apart from iatrogenic injury at the time of arthroscopic knee surgery, this syndrome is most commonly seen in cyclists and rowers where the presumed mechanism relates to repetitive knee flexion.

**2.1.4 Investigation**

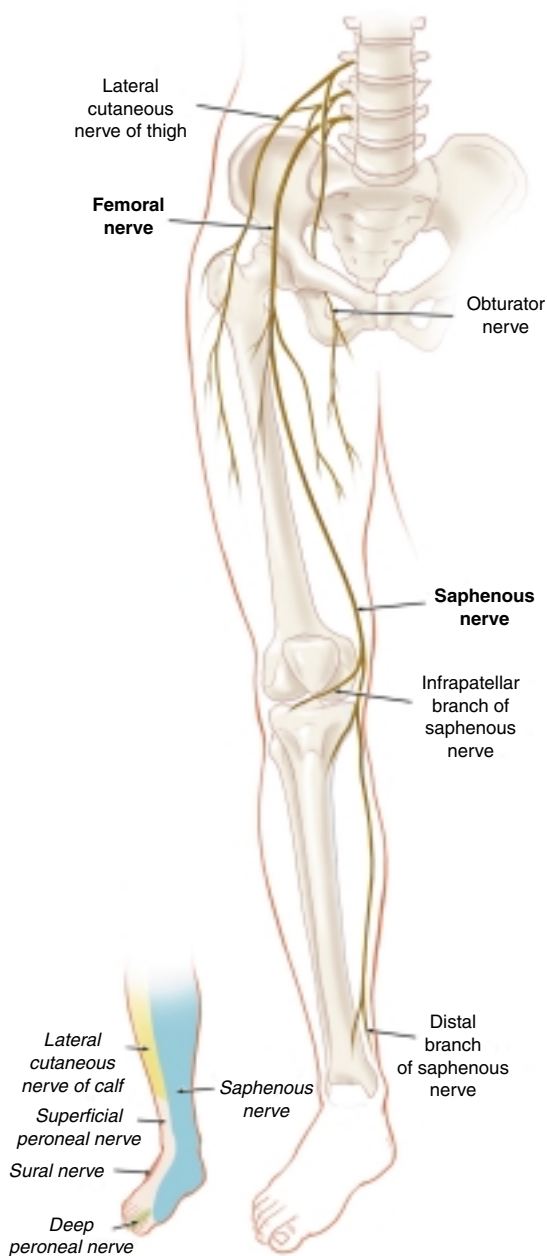
Where diagnostic uncertainty exists, a local anaesthetic block of the nerve within the adductor canal may help isolate the syndrome. Often post-exercise examination of the patient, with or without a local anaesthetic block, may be the crucial diagnostic step.

**2.1.5 Management**

Treatment may either be conservative or involve surgical neurolysis.<sup>[19,20]</sup> Conservative treatment includes physiotherapy, ‘neuromeningeal’ stretching and soft tissue massage.

**2.1.6 Surgical Management**

Surgical treatment of saphenous nerve entrapment, in general, involves exposure of the saphenous nerve in the subsartorial canal. The incision is approximately 10cm proximal to the patella, an-



**Fig. 3.** Anatomy of the saphenous nerve.

terior to the sartorius. The interval between quadriceps and sartorius is developed. The next layer encountered is the fascia between the vastus medialis and the adductor magnus. This is incised to expose the saphenous nerve.

There is then argument as to whether neurolysis of the nerve or neurectomy gives the best result. One of the more detailed reports on surgical management of this condition reported 15 patients with complete relief of symptoms in 13 knees. At the end of the study it was concluded that neurectomy gave a more predictable result than neurolysis.<sup>[17]</sup> The main problem with division of the saphenous nerve is the distal anaesthesia, which some patients find quite annoying.

If neurolysis is carried out all fascial bands around the saphenous nerve must be divided in the more distal regions of the subsartorial canal (figure 3). If neurectomy is performed then the nerve is divided **proximal to the fascia in the canal between the vastus medialis and adductor magnus. The best management for the cut proximal nerve is to suture into an adjacent muscle belly** so that any distal neuroma will be less likely to cause future problems.

**The nerve can also be compressed as it travels between the sartorius and gracilis muscles near their insertion. The nerve can either be released or divided in this region.**

**Probably the most frequently seen problem in the sporting population is a neuroma of the infrapatellar branch. This can be irritated by repetitive movement of the knee or by direct pressure producing symptoms from the neuroma. Surgical treatment is simple. A straight incision is made over the neuroma, which is then excised, dividing the infrapatellar branch fairly proximally.**

## 2.2 Common Peroneal Nerve

### 2.2.1 Anatomy

The common peroneal nerve (CPN) leaves the sciatic nerve in the distal thigh and lies on the biceps femoris muscle and tendon to the popliteal fossa. It then runs laterally in an exposed fibro-

osseous tunnel at the level of the fibular neck and passes below the tendinous origin of peroneus longus and enters the peroneal tunnel between the two heads of this muscle. Proximal to the fibular head, the lateral sural cutaneous nerve branches from the CPN and passes distally. As the nerve enters the peroneal tunnel, the CPN divides into the deep, superficial and recurrent peroneal nerves. These nerves stretch over the periosteum of the fibular neck and are covered by the tendinous origin of the peroneus longus muscle at this point. Plantar flexion or ankle inversion tenses peroneus longus and compresses the nerve in the tunnel against the fibula neck (figures 4 and 5).

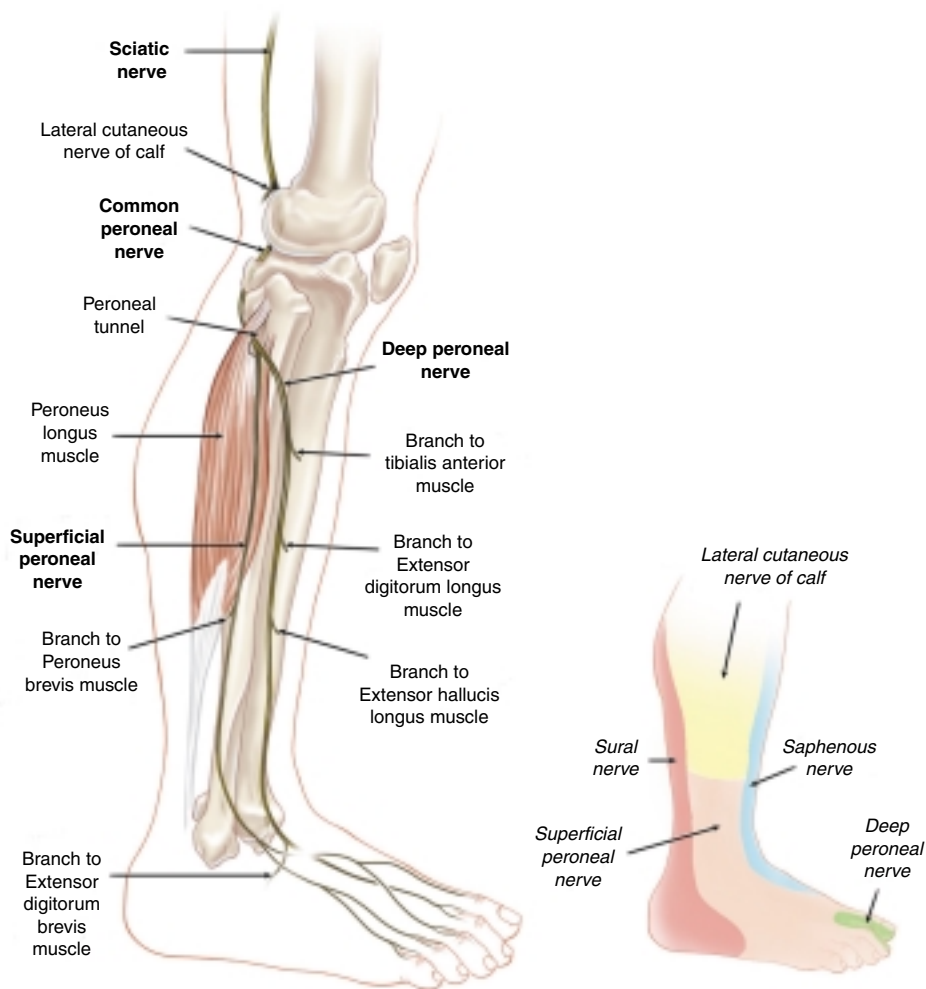
The superficial peroneal nerve (SPN) runs between the fibula and the peroneus longus muscle and courses distally lying on the anterior intermuscular septum. The SPN supplies both peroneal muscles. At the junction of the middle and distal third of the tibia, the nerve pierces the crural fascia and splits into two cutaneous branches. This nerve may be compressed by the crural fascia (the SPN syndrome) or where the terminal branches cross the anterior aspect of the ankle joint sub-cutaneously. The terminal branches provide the sensation to the anterolateral leg, the dorsum of the foot and the dorsal skin of the great, second, third and medial fourth toes.

The deep peroneal nerve (DPN) pierces the anterior intermuscular septum and travels with the anterior tibial blood vessels between the tibialis anterior and either the extensor digitorum longus proximally or extensor hallucis longus distally. In this fashion, these muscles receive their innervation from the DPN. The nerve enters the foot under the cruciform ligament and supplies the sensation to the skin between the great and first toes and a medial branch to the extensor digitorum brevis muscle.<sup>[21]</sup>

### 2.2.2 Aetiology

Injury to the main trunk of the CPN in the region of the peroneal (or fibular) tunnel frequently is caused by an external compressive source such as tight plaster casts, knee surgery, osteophytes, sy-





**Fig. 4.** Anatomy of the common peroneal nerve and its branches.

novial cysts or ganglions, sitting in a prolonged crossed leg position (figure 5). Functional anatomical changes such as repetitive exercise involving inversion and pronation (e.g. runners, cyclists and machine operators) stretch the CPN against the fibular and fibrous arch of the peroneal tunnel resulting in the clinical syndrome. Many cases are idi-

opathic in origin.<sup>[13,22]</sup> Only few cases of CPN entrapment have been reported in runners.<sup>[23-25]</sup> Involvement of the CPN or its branches may also be seen in conjunction with compartment syndromes, the DPN with an anterior compartment syndrome and the SPN with a lateral compartment syndrome.<sup>[26]</sup> Examination of the patient after exercise

and palpation of muscle compartments and assessment of vascular function is important in the diagnostic workup of this problem.

### 2.2.3 Clinical Presentation

#### Common Peroneal Nerve (CPN) Syndrome

In all reported cases running or other exercise resulted in leg pain and numbness. Examination post-exercise confirmed the presence of muscle weakness, paraesthesia and a positive Tinel's sign

at the level of the fibular neck. All patients were treated surgically after failure of conservative management with a high (90%) success rate. The usual clinical syndrome involves pain in the region of the nerve compression that subsequently spreads to the sensory distribution of the nerve. This exercise-related pain often resembles that of an anterior compartment syndrome. In our experience, the subjective numbness may be variable in distribution and is typically described as a characteristic

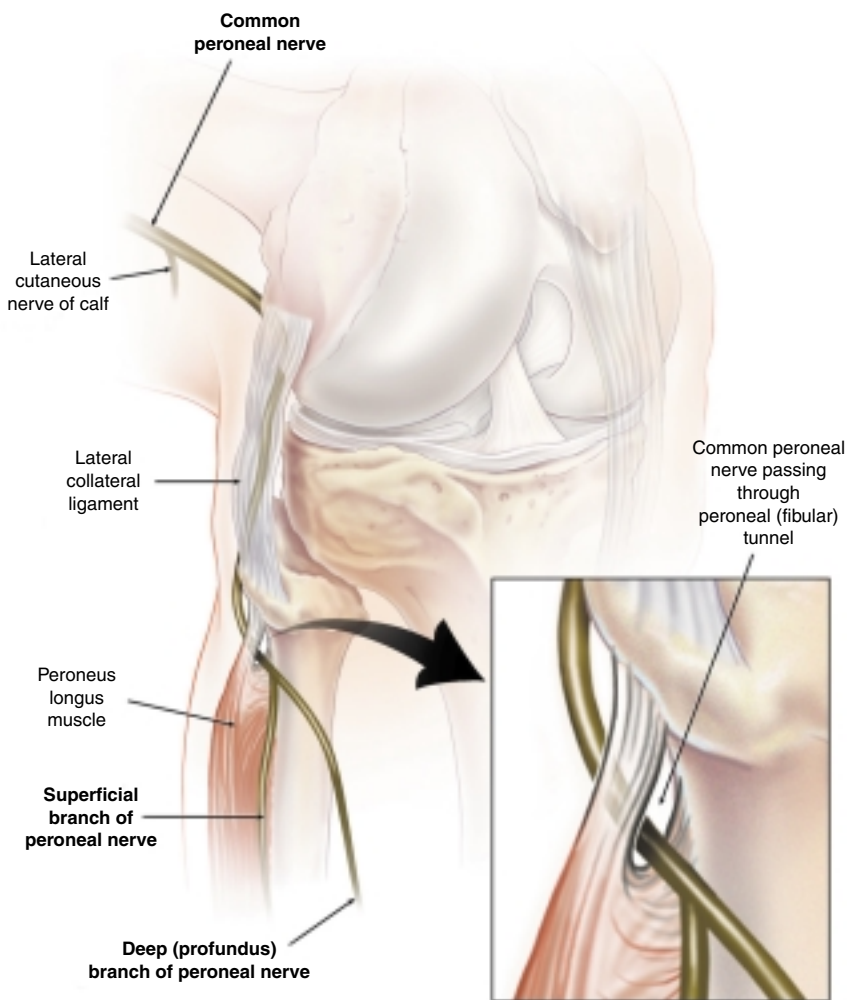


Fig. 5. Anatomy of the peroneal (or fibular) tunnel.

'burning' sensation rather than 'pins and needles' or a 'loss' of sensation. Compression or percussion of the nerve in the peroneal tunnel will usually increase the patient's pain but not their other sensory symptoms. Patients will usually have post-exercise weakness of ankle dorsiflexion and inversion. Forced inversion may increase the pain. Flaccid motor weakness, such as foot drop, is typically seen only late in the syndrome.

#### Superficial Peroneal Nerve (SPN) Syndrome

Clinical signs of the SPN syndrome include pain or anaesthesia over the lateral calf and/or dorsum of the foot with resisted ankle dorsiflexion and eversion.<sup>[21,27,28]</sup> SPN entrapment has been reported in runners, soccer players, jockeys, tennis players, bodybuilders and dancers.<sup>[12]</sup> In these cases, loss of sensation during exercise over the lateral distal calf or dorsum of the foot was noted. Relief by conservative measures was uncommon.<sup>[27,29]</sup>

#### Deep Peroneal Nerve (DPN) Syndrome

All reported sports-related cases of DPN entrapment relate to anterior tarsal tunnel syndrome (TTS) with symptoms referable to the dorsum of the foot rather than the lower leg.<sup>[12]</sup>

### 2.2.4 Investigations

The diagnosis may be confirmed with electromyography and nerve conduction studies that will usually demonstrate a localised slowing of CPN conduction across the peroneal tunnel. Specific electrophysiological techniques also exist for the SPN and DPN branches.<sup>[30,31]</sup> Treatment may be conservative with modification of the precipitating activity or biomechanical correction, or if this is unsuccessful, surgical decompression. If an underlying compartment syndrome is diagnosed with appropriate pre- and post-exercise compartment pressure studies then surgical decompression is recommended.

### 2.2.5 Surgical Management

#### CPN

If the CPN is compressed around the fibula neck there are two common conditions that require surgical treatment. The first is compression of the

nerve related to a ganglion cyst arising from the proximal tibio-fibula joint. In most cases, the ganglion reaches the nerve via the sensory branch, which innervates the joint.<sup>[32,33]</sup> Surgical treatment for this condition is with excision of the ganglion cyst, which is followed proximally to the tibio-fibular joint where it is excised, together with an area capsule in the joint, to try and prevent recurrence. Following this a neurolysis is carried out of the nerve around the neck of the fibula, which may require meticulous dissection. It has been suggested that restoration of nerve function is better if the surgery is carried out early.<sup>[25,34]</sup>

The authors have found that the most common condition seen in our sports medicine practice is compression neuropathy of the peroneal nerve around the fibular neck. This is related to pressure from the overlying muscle and fascia, particularly in the area where the nerve travels under the sharp fibrous edge of the peroneus longus origin<sup>[23]</sup> (figure 5). We have found good relief of symptoms with release of the nerve around the fibular neck.

Surgical procedure for CPN compression around the fibular neck involves an oblique incision along the course of the nerve. The fascia over the peroneal muscles is divided exposing the deeper muscle belly, which is divided, exposing the nerve, together with the sharp fibrous edge at the proximal entry of the nerve into the peroneus longus. The recovery from decompression of the CPN of the fibular neck region is usually quite rapid and patients can be running within 2 to 3 weeks.

#### SPN

Operative treatment involves release and decompression of the nerve. The exact procedure depends on the pathology present. If there is a chronic compartment syndrome, which in our experience is uncommonly associated with this condition, then a standard compartment decompression is carried out. It is then important to identify the course of the superficial branch where it travels from the peroneal to the anterior compartment. The anatomy in this region is extremely variable and all sites of potential compression need to be released. An oc-

casional finding is compression of the nerve by a muscle herniation through a fascial hiatus. This can even produce localised narrowing of the nerve. The pathology, in this situation, is enlargement of a normal vascular fascial hiatus, due to the underlying compartment syndrome, in an area where the nerve courses over the hiatus. With exercise, particularly when a compartment syndrome is present, the underlying muscle belly herniates through the fascial defect, compressing the nerve. In this situation, it is important to divide the fascia through the defect, extending this at least 5cm proximally and distally.

When a compartment syndrome is not associated with SPN compression, the nerve is usually compressed where it exits through the deep fascia,<sup>[35]</sup> or more distally.<sup>[36]</sup> In this situation a more distal incision is necessary than for a compartment decompression. A longitudinal incision is made anterior to the fibula and just proximal to the lateral malleolus. Through this the fascia over the nerve at the exiting tunnel can be divided, together with division of any fascia covering the branching nerve in the region of the transverse extensor retinaculum (transverse crural ligament). Styf<sup>[27]</sup> reported that only 9 of the 19 in their series were completely satisfied with the procedure and this would reflect our experience. It appears that there can be chronic irreversible damage to the nerve in this condition. A form of 'tension neuropathy' has also been proposed for this distal form of SPN entrapment and this responds to surgical release.<sup>[37,38]</sup>

#### DPN

Most cases with this condition seen in our clinic have been related to compartment syndrome with good relief following decompression of the anterior and peroneal compartments. Less commonly seen, but well described is the anterior TTS.<sup>[31]</sup> In this condition, the nerve is compressed under the extensor retinaculum. Compression has also been described under the extensor hallucis brevis, and over dorsal osteophytes of the talo-navicular joint.

The nerve in all these areas is very superficial. The surgical approach is therefore directly over the

site of compression with resection of the osteophyte and neurolysis.

## 2.3 Sural Nerve

### 2.3.1 Anatomy

The sural nerve usually originates from two main branches, the medial cutaneous sural nerve from the tibial nerve and the ramus communicans of the lateral cutaneous sural nerve of the common peroneal nerve. However, in up to 20% of cases, based on cadaver studies, the origins and course of the sural nerve were variably absent.<sup>[22,39]</sup>

The sural nerve begins with its main component from the tibial nerve in the popliteal fossa and then runs distally between the two heads of gastrocnemius beneath the crural fascia. Between the middle and distal thirds of the calf, the nerve pierces the fascia and runs distally near the small saphenous vein lateral to the Achilles tendon. It anastomoses with the common peroneal branch at different levels. The sural nerve then passes behind the lateral malleolus to supply the ankle joint, the posterior calf and the lateral side of the heel and foot (figure 6).<sup>[12]</sup>

### 2.3.2 Aetiology

Although not commonly reported as a cause of exercise-related leg pain nevertheless, compression of the nerve caused by mass lesions, scar tissue, ganglia, surgical trauma and thrombophlebitis have all been reported. Extrinsic compression from tight ski boots and casts may similarly induce this problem. The crural fascia may act as either a compression point or a fixation point for the nerve and athletic activities such as running or track sports may stretch the nerve at this level. Similarly, repetitive ankle inversion injuries may lead to fibrosis and nerve entrapment.<sup>[3,15,40-42]</sup>

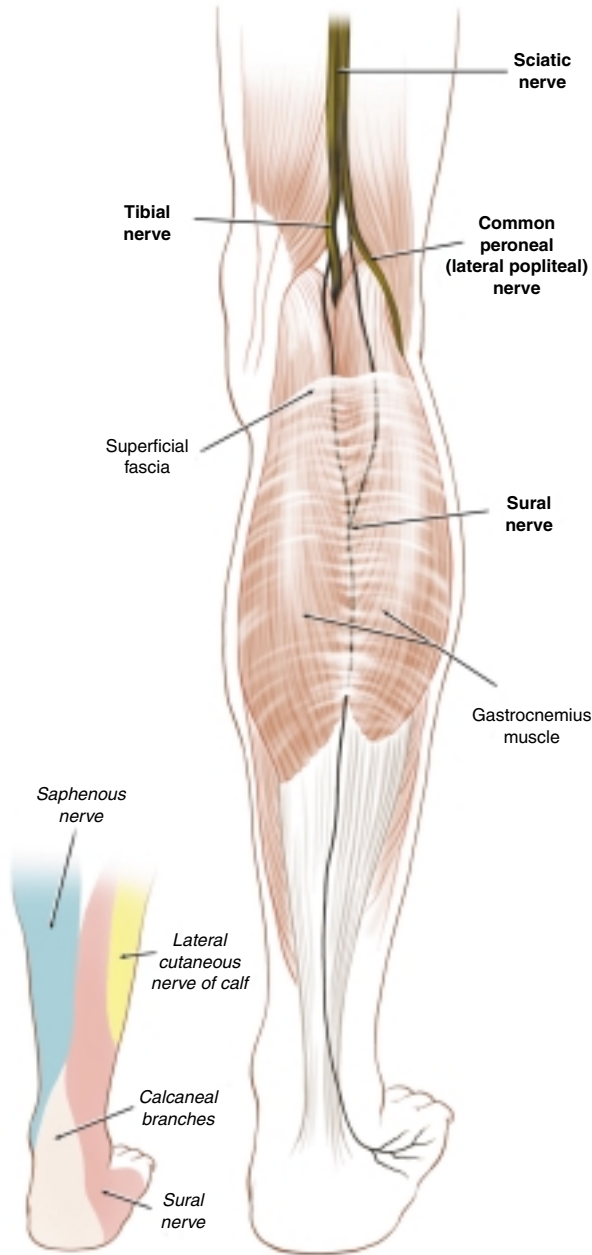
### 2.3.3 Clinical Presentation

Clinically, patients usually report shooting pain or dysaesthesias in the cutaneous distribution of the nerve although objective signs may not always be present. In our experience, this neurogenic pain is often confused with that of pathology in the tendo calcaneus and many athletes present to

sports physicians with ‘recurrent’ Achilles tendonitis or ‘tears’. The use of nerve conduction studies to assist in diagnosis has been reported.<sup>[43]</sup>

**2.3.4 Management**

Treatment of this condition depends on the accurate clinical, radiological or electrophysiologi-



**Fig. 6.** Anatomy of the sural nerve.

cal identification of the lesion site. Depending upon the nature of the underlying pathology or biomechanical cause either a conservative or surgical approach may be considered.

### **2.3.5 Surgical Management**

In the areas of potential entrapment, the sural nerve is quite superficial and therefore once the region of entrapment has been delineated, the surgical procedure is relatively simple.<sup>[41]</sup> A longitudinal incision is made over the involved area and the overlying tissues within the subcutaneous region divided. In the area around the heads of the gastrocnemius this may involve a long proximal dissection between the two muscle bellies.

## **2.4 Tibial Nerve**

### **2.4.1 Anatomy**

The tibial nerve originates from the anterior divisions of L4-S3 via the medial trunk of the sciatic nerve. The sciatic nerve divides into the common peroneal and tibial nerves at the level of the popliteal fossa and the tibial nerve continues distally deep to gastrocnemius. In the calf this nerve supplies the muscular innervation to gastrocnemius, soleus, tibialis posterior, flexor digitorum longus and flexor hallucis longus. Approximately 15cm above the ankle, the nerve becomes superficial passing medial to the Achilles tendon. The nerve then passes underneath the flexor or medial retinaculum of the ankle joint that forms the 'roof' of the tarsal tunnel. At the level of the tarsal tunnel the nerve divides into the medial and lateral plantar nerves as well as the medial calcaneal branch that supplies the sensation to the medial aspect of the heel (figure 7).<sup>[44,45]</sup>

The tarsal tunnel is bridged by the retinaculum and the medial border of the tunnel is the talus and calcaneus. The tibial nerve and its distal branches pass in distinct fascial tunnels separate to the other contents of the tarsal tunnel which include the posterior tibial vessels and the tendons of tibialis posterior, flexor digitorum longus and flexor hallucis longus.<sup>[46]</sup> Compression of neural structures is known as the TTS (figure 8).

The medial plantar nerve reaches the sole of the foot by passing under the origin of abductor hallucis and through a fibro-osseous space formed by the attachment of flexor hallucis brevis to the calcaneus. The lateral plantar nerve passes separately under the abductor hallucis and then passes between flexor digitorum brevis and quadratus plantae. The lateral plantar nerve gives off a mixed sensory-motor branch that passes in close relation to the plantar facial attachment to the calcaneum. This nerve ultimately innervates the abductor digiti quinti muscle. Injury to or entrapment of this branch has been reported as a cause of persistent heel pain.<sup>[47-53]</sup> Both plantar nerves end by forming the interdigital nerves, the medial plantar forming the branches to the medial three-and-a-half toes and the lateral plantar supplying the lateral one-and-a-half toes. The plantar nerves give the muscular innervation to all of the intrinsic foot muscles.

### **2.4.2 Aetiology**

From a clinical standpoint, injury or entrapments affecting the tibial nerve in the leg are rare.<sup>[54]</sup> In the popliteal fossa, Baker's cysts, popliteal artery aneurysms and ganglia can compress the nerve but no specific sport or exercise-related conditions have been reported.<sup>[55]</sup> By contrast, entrapment of the distal branches, most notably the posterior tibial nerve as it passes through the tarsal tunnel are extremely common in sport.<sup>[56,57]</sup>

The branches of the tibial nerve may also be entrapped distal to the tarsal tunnel in a variety of specific clinical syndromes. Although the causes of such injuries are generally the same as for the TTS, anatomically the point of entrapment tends to be separate. The medial plantar nerve may become entrapped where it passes under the fibrous arch of the abductor hallucis origin and through the fibro-osseous space formed by the attachment of flexor hallucis brevis to the calcaneus.<sup>[3,58-60]</sup> The authors have seen a number of cases of isolated medial plantar nerve entrapment in ballet dancers requiring surgical neurolysis for definitive cure. Isolated injuries to the lateral plantar nerve have also been reported in gymnasts.<sup>[61]</sup>

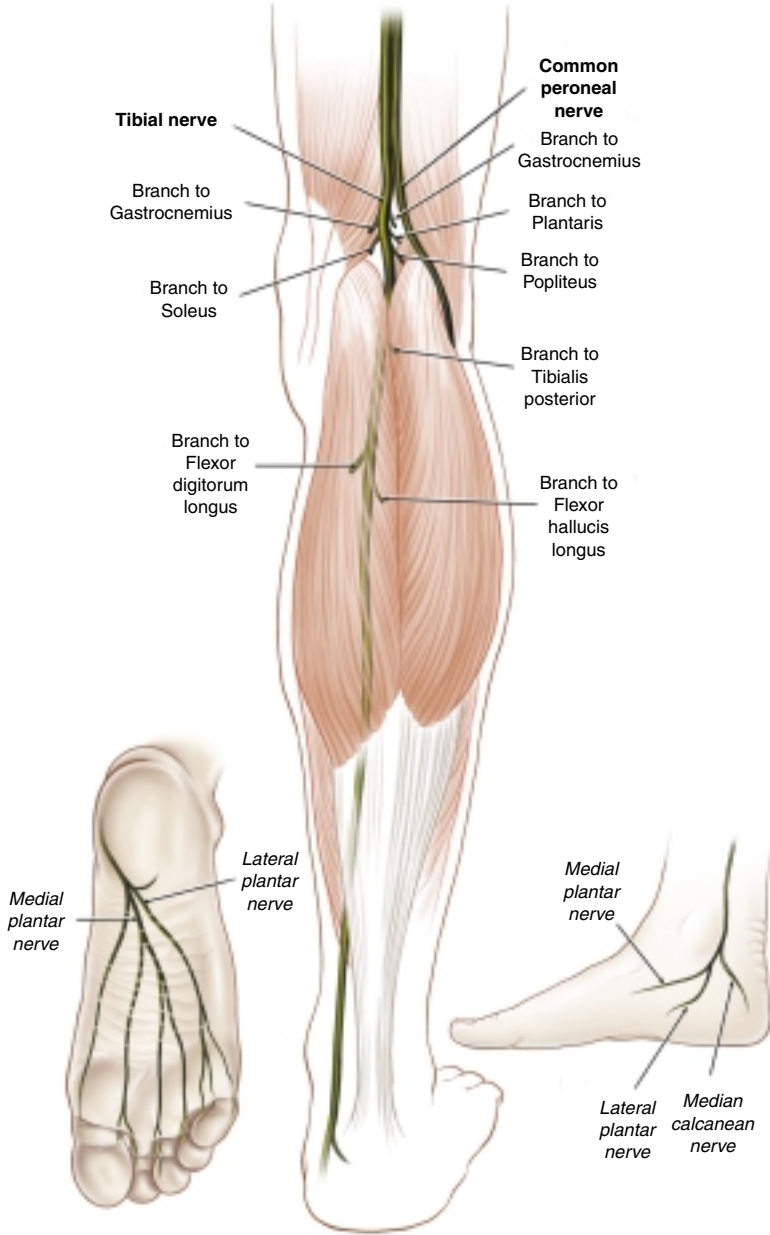


Fig. 7. Anatomy of the tibial nerve.

The first sensory-motor branch of the lateral plantar nerve may be entrapped between the muscle layers or where it passes in close relation to the plantar facial attachment to the calcaneum. Injury

to or entrapment of this branch has been reported as a cause of persistent heel pain, although no neurological abnormalities are evident and the nerve can not be electrophysiologically tested. Surgical

decompression may be successful in the management of this condition.<sup>[3,62]</sup>

The medial calcaneal branch of the tibial nerve may be entrapped in a TTS depending on the level of branching. An ankle joint ganglion within the tarsal tunnel has been reported as a cause of entrapment of this particular nerve.<sup>[63]</sup> In the authors' experience most cases of neuropathy affecting this nerve are secondary to extrinsic compression or local trauma not involving a TTS.

**2.4.3 Clinical Presentation**

Damage to the tibial nerve or its branches within the tarsal tunnel cause a characteristic clinical syndrome of pain and/or paraesthesia in the foot.<sup>[64]</sup> In the majority of cases, the TTS is secondary to external pressure, mass lesion or local bony and ligamentous trauma to the ankle. In the sporting situation, local tenoperiostitis has been cited as a potential cause although the clinical descriptions

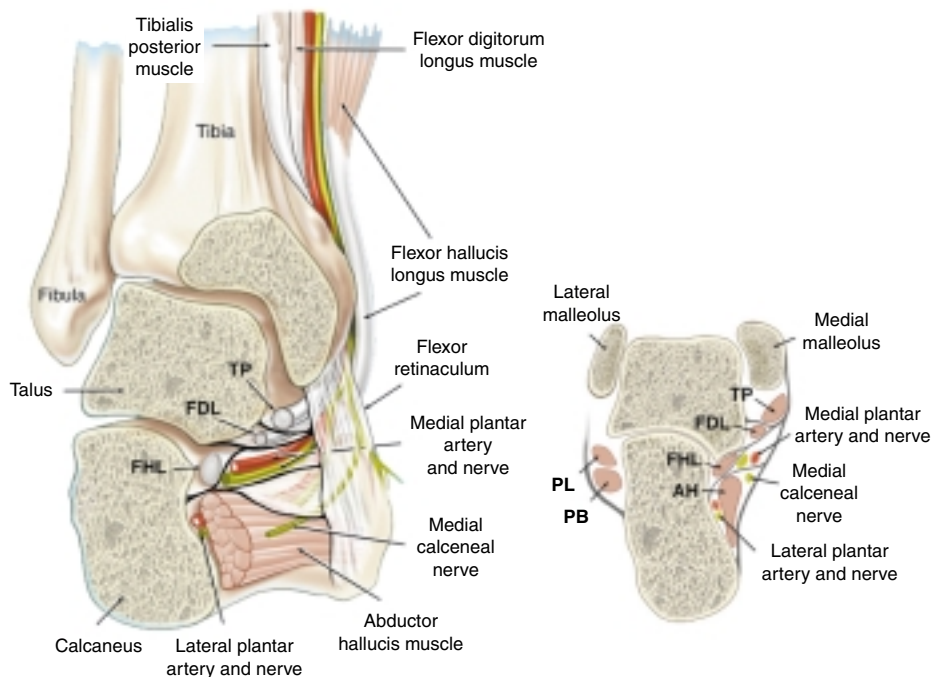
of this in athletes are generally poor with the more likely cause being biomechanical compression due to rear foot pronation in such cases. Foot and ankle position has a marked influence on tarsal tunnel compartment pressure.<sup>[65]</sup> In many cases, idiopathic fibrosis or ligamentous thickening have been the operative findings in typical cases.<sup>[3,59,66-72]</sup>

**2.4.4 Investigation**

Investigation strategies for a suspected TTS should include nerve conduction studies and electromyography.<sup>[73]</sup> Numerous articles have been published discussing electrophysiological techniques in this regard.<sup>[9,74-77]</sup> In addition, MRI may be useful to delineate the tarsal tunnel more accurately or if a local lesion or tumour is suspected.<sup>[11,78-81]</sup>

**2.4.5 Management**

Treatment of TTS in the first instance should be directed at correction of biomechanical abnormal-



**Fig. 8.** Anatomy of the tarsal tunnel. AH = abductor hallucis; FDL = flexor digitorum longus; FHL = flexor hallucis longus; PB = peroneus brevis; PL = peroneus longus; TP = tibialis posterior.



ities using orthotic devices, and footwear modification may be required. The use of local corticosteroid injections or anti-inflammatory treatment may be useful in reducing inflammation if present, which may in turn reduce swelling in the tarsal tunnel providing relief of symptomatic nerve compression. It is important to note, however, that nerve injury may result from incorrect injection technique and that because of the complex anatomy, any injection must be inserted in the correct anatomical plane to be effective (figure 8). If conservative modalities fail to resolve the problem and the symptoms are severe or disabling, then consideration of surgical exploration is necessary.<sup>[82,83]</sup>

#### **2.4.6 Surgical Treatment of Tarsal Tunnel Syndrome**

A longitudinal incision is made mid-way between the medial malleolus and the Achilles tendon. The dissection is continued down to the sheath of the flexor digitorum longus. In the plane over this tendon the dissection is then carried more posteriorly. The neurovascular bundle is then identified. There are usually one or two small vessels coursing anteriorly in this region that need division with a bipolar diathermy. The proximal portion of the flexor retinaculum is identified and the entire retinaculum is then divided just posterior to the flexion digitorum longus, taking care not to injure the underlying neurovascular structures. Neurolysis is then carried out of the tibial nerve, which can be followed to its division into the medial and lateral plantar nerves.

In cases where it is felt that the entrapment is also distal to the tarsal tunnel, then a similar procedure is carried out. However, dissection is carried more distally. The fibrous arch of the abductor hallucis origin, and the fibro-osseous space formed by the attachment of the flexor hallucis brevis is divided. If clinically indicated, either the medial calcaneal branch of the tibial nerve or the lateral plantar nerve and its first sensory branch can be followed distally and overlying compressive structures divided, with appropriate neurolysis. The medial calcaneal branch in at least 20% of cases con-

sists of multiple nerve branches. In one study, multiple branches were found in 60% of cases.<sup>[84]</sup> To expose the lateral plantar nerve, it is not infrequently necessary to take down a portion of the dorsal half of the origin of abductor hallucis from the calcaneus, which is usually a dense fibrous band.

## 2.5 Plantar Interdigital Nerves

### **2.5.1 Anatomy**

The interdigital nerves are formed from the terminal branches of the medial and lateral plantar nerves and pass distally alongside the metatarsal bones and cross the deep transverse metatarsal ligaments (figure 7). The two syndromes that are commonly recognised affecting these nerves in both athletes and nonathletes are neuromas of the plantar interdigital nerves (Morton's neuroma) and the medial plantar proper digital nerve (Joplin's neuritis).

#### Morton's Neuroma

##### **Aetiology**

Morton's neuromas result from damage to an interdigital nerve where it lies on the deep transverse metatarsal ligament between the heads of adjacent metatarsal bones. This damage results in a fibrotic nodule forming at that site with varying demyelination of the involved nerve.<sup>[85]</sup> Although colloquially described as a 'neuroma', in fact the pathology is more typical of peri-neural fibrosis.<sup>[86]</sup>

##### **Clinical Presentation**

Clinically, the patient complains of forefoot pain that radiates into the toes that may or may not be accompanied by a persistent sensory disturbance. The characteristic pain is described as a lancinating or shooting pain when the metatarsal heads are compressed. Standing or walking usually exacerbates symptoms, particularly when wearing tight shoes.

##### **Investigation**

Morton's neuromas can be directly imaged by ultrasound, computed tomography and MRI scanning and the nerve can be tested electrophysiologically.<sup>[87-89]</sup>

## Management

Treatment may be conservative especially if the symptoms are mild.<sup>[90]</sup> Footwear modification, metatarsal padding and corticosteroid infiltration have all been reported with varying degrees of success. If conservative measures are unsuccessful and/or the symptoms severe, then surgical excision of the neuroma, often combined with internal neurolysis, is the usual treatment.<sup>[91-93]</sup>

### Surgical Treatment of Morton's Neuroma

This has been described utilising either a plantar or a dorsal approach. Controversy exists as to the best surgical approach to this problem.<sup>[94]</sup> The dorsal approach avoids making a scar on the sole of the foot. The transverse metatarsal ligament needs to be divided, and there is danger of damage to the dorsal cutaneous nerves in the web space.

The authors have mainly utilised a plantar approach. A longitudinal incision is made, which must be accurately placed in the inter-space between the metatarsal heads. Only sharp dissection with a knife should be carried out to avoid damage to the underlying fatty tissue. At times a large bursa may be present which needs to be removed. The common digital nerve is identified and traced to its bifurcation and it is in this region that the 'neuroma' occurs. The branches of the nerve are divided and the common digital nerve is then cut proximal to the metatarsal head. The wound is closed with interrupted suture.

### Joplin's Neuritis

#### Aetiology

Joplin's neuritis is caused by a neuropathic injury to the medial plantar proper digital nerve, either where it crosses the first metatarso-phalangeal joint or on the medial aspect of the great toe. This is usually caused by chronic compression or irritation from inadequate footwear.<sup>[95]</sup>

#### Clinical Presentation

Typically the patient complains of pain and paraesthesia on the medial side of the great toe when walking. In the authors' experience, the symptoms often commence after wearing particularly tight shoes and then remain as a persistent area of

localised sensory disturbance. There may additionally be a biomechanical forefoot abnormality that predisposes the individual to this problem. The diagnosis may be confirmed by nerve conduction studies. Treatment may be conservative with footwear modification or surgical excision of the nerve performed for disabling or persistent pain.<sup>[96-98]</sup>

### Surgical Treatment of Joplin's Neuritis

Joplin's neuritis involves entrapment of the proper digital nerve adjacent to the medial sesamoid. Operative treatment may involve surgical neurolysis and transposition of the nerve away from the sesamoid or shaving a portion of the sesamoid to assist in decompressing the nerve. A less common condition is entrapment of the lateral proper digital nerve. It lies beneath the transverse metatarsal ligament, which produces pressure which then flattens the nerve. If symptoms are severe, then surgical treatment involves division of the deep transverse ligament and neurolysis of the nerve.

## 3. Other Neurogenic Causes of Exercise-Related Lower Limb Symptoms

Apart from the focal nerve entrapment syndromes, patients with other neurological conditions may present with symptoms referable to the lower limb. These may include myopathies, polyneuropathies, exercise-related cramps or leg weakness due to proximal nerve injury. Muscle pain may occur following unaccustomed or extreme exercise and may be severe and delayed in onset in its presentation. Clinicians need to be alert to the differential diagnostic possibilities in this situation and the patient history is the most important aspect of the overall assessment.

A patient with an underlying myopathic or neurogenic condition may present with a variety of symptoms. A feeling of 'weakness', 'fatigue' or 'tiredness' is not unusual. Subjective muscle pain is uncommonly reported in adults although muscle tenderness may be noted. Localised muscle wasting may be present particularly in the inherited

muscle diseases. If there is florid muscle weakness then the patient may present for diagnosis; however, more usually a concerned parent or coach usually notices the weakness that may be more evident following exercise. These symptoms are often bilateral and usually develop slowly. Some possible diagnoses are listed in table II.

### 3.1 Muscle Cramp Syndromes

Muscle cramps represent sudden, involuntary and often painful shortening of muscle, and may be attended by visible ‘knotting’ of the muscle which may in turn lead to abnormal posturing of the affected joint. These are perhaps the most common neuromuscular disorders to affect an athlete and occur universally. For the most part their origin is benign. The common cause of muscle cramps is muscle fatigue; however, other factors such as dehydration, vascular insufficiency, electrolyte imbalance or unaccustomed muscle activity may be associated. Rare pathological causes include motor neuron disorders, hypothyroidism, muscle enzyme disorders or specific movement disorders such as Isaac’s syndrome. Treatment is usually symptomatic and prevention by stretching, graduated exercise programmes and ensuring adequate hydration before exercise is all that is usually required.<sup>[99]</sup>

## 4. Overlap of Clinical Syndromes Causing Exercise-Related Leg Pain

There is considerable clinical overlap between vascular entrapment, compartment syndromes and focal nerve entrapments in cases of exercise-related leg pain. In some situations (e.g. with compartment syndrome affecting the peroneal or deep posterior compartments), exercise will produce neurogenic symptoms. Similarly, popliteal artery entrapment may produce neural ischaemia resulting in focal neurological symptoms.

The astute clinician must first be aware of the various causes of exercise-related leg pain and their overlap, second, examine the patients following provocative exercise whilst the typical symp-

toms are present and third, appropriately investigate suspected cases to establish a pathophysiological diagnosis before definitive management. For most sports medicine clinicians, the common causes of exercise-related leg pain relate to tibial stress fractures and other muscular problems. In cases where the presentation is atypical or where the patient describes prominent neurological symptoms or where the initial bone investigations are unrevealing then consideration of the conditions described in this review may be helpful.

In a number of nerve entrapment syndromes involving the lower leg, a coexistent compartment syndrome is often diagnosed by the use of compartment pressure studies. It has been our practice in this situation to carry out compartment decompression in addition to neurolysis of the involved nerve. For example, where a SPN entrapment is noted and a clinical history of compartment syndrome is elicited despite equivocal pressure studies, a dual procedure is performed. In this procedure, a longitudinal incision is made ~4cm long, just anterior to the lateral intramuscular septum in

**Table II.** Causes of neurogenic lower limb weakness and pain other than nerve entrapments

Myopathic	Inflammatory myopathies – polymyositis or dermatomyositis
	Endocrine, toxic or drug-induced myopathies
	Muscle dystrophies – limb girdle, scapulo-peroneal
	Myotonic dystrophy
	Acid maltase deficiency
	Benign congenital myopathies – nemaline, myotubular
Neuromuscular blocking disorders	Myasthenia gravis
	Lambert-Eaton syndrome
	Guillain-Barre syndrome
	Chronic demyelinating polyneuropathy
Neurogenic	Diabetic amyotrophy
	Root or lumbar plexus lesion
	Motor neuron disease
	Spinal muscle atrophy
Other	Atrophy of muscles caused by joint disease
	Upper motor neuron lesion

the mid-anterior compartment region. The anterior compartment fascia is divided longitudinally and a window of fascia is removed.<sup>[100]</sup> The peroneal compartment fascia is then divided longitudinally and transversely, with removal of the smaller area of fascia and the lateral intramuscular septum is also divided. The superficial branch of the peroneal nerve is identified and released as described above.

An overlap of different aetiological causes for clinical nerve entrapment syndromes is commonly seen in sports medicine. In general terms, surgical decompression for localised nerve compression fares better where a clear anatomic distribution of pain exists. Caution must be exercised for those patients with non-anatomical complaints of pain or where additional neurological diagnoses exist such as peripheral neuropathy or fibromyalgia. Even athletes with long standing complaints of pain can do well with surgery, if carefully selected.

## 5. Conclusion

Numerous pathologies in the lower limb may present with chronic exercise-related leg pain. Focal nerve entrapment syndromes represent a small but important group of conditions presenting to the sports physician. A detailed understanding of the anatomical basis and clinical presentation of such conditions is presented in this article in order to guide clinicians in their management of such problems. Many of the clinical presentations overlap and many of the described conditions coexist. We raise the possibility of a common pathophysiological basis of many of these presentations; namely fascial dysfunction. At the present time, however, the biochemical or genetic basis for such 'fasciopathies' is unclear and should be an important direction of research in the future. Definitive surgical management of focal nerve entrapments should be based upon an appropriate clinical presentation accompanied by electrophysiological abnormalities if treatment failure is to be avoided.

## Acknowledgements

The authors have no conflicts of interest.

## References

1. Peri G. The 'critical zones' of entrapment of the nerves of the lower limb. *Surg Radiol Anat* 1991; 13 (2): 139-43
2. McCluskey LF, Webb LB. Compression and entrapment neuropathies of the lower extremity. *Clin Podiatr Med Surg* 1999; 16 (1): 97-125, vii
3. Schon L, Baxter D. Neuropathies of the foot and ankle in athletes. *Clin Sports Med* 1990; 9 (2): 489-509
4. Baxter DE. Functional nerve disorders in the athlete's foot, ankle, and leg. *Instr Course Lect* 1993; 42: 185-94
5. Fernandez E, Pallini R, Lauretti L, et al. Neurosurgery of the peripheral nervous system: entrapment syndromes of the lower extremity. *Surg Neurol* 1999; 52 (5): 449-52
6. Biundo Jr JJ, Harris MA. Peripheral nerve entrapment, occupation-related syndromes and sports injuries, and bursitis. *Curr Opin Rheumatol* 1993; 5 (2): 224-9
7. Bickerstaff E, Spillane J. Neurological examination in clinical practice. 5th ed. London: Blackwell Scientific Publications, 1989
8. Wilbourne A. Electrodiagnostic testing of neurologic injuries in athletes. *Clin Sports Med* 1990; 9: 229-45
9. Stewart J. Focal peripheral neuropathies. 3rd ed. New York: Lippincott Williams and Wilkins, 2000
10. Martinoli C, Bianchi S, Gandolfo N, et al. US of nerve entrapments in osteofibrous tunnels of the upper and lower limbs. *Radiographics* 2000; 20 Spec No.: S199-213
11. Erickson S, Quinn S, Kneeland J. MR imaging of the tarsal tunnel and related spaces: normal and abnormal findings with anatomical correlation. *Am J Roentgenol* 1990; 155: 323-8
12. Pecina M, Krmpotic-Nemanic J, Markiewitz A. Tunnel syndromes: peripheral nerve compression syndromes. 3rd ed. Boca Raton (FL): CRC Press, 2001
13. Kopell HP, Thompson W. Peripheral nerve entrapments of the lower extremity. *New Engl J Med* 1962; 266: 16-9
14. Kopell H, Thompson W. Peripheral entrapment neuropathies. Baltimore (MD): Williams and Wilkins, 1963
15. Deese J, Baxter D. Compressive neuropathies of the lower extremity. *J Musculoskel Med* 1988; 5: 678-95
16. Dumitru D, Windsor R. Subartorial entrapment of the saphenous nerve of a competitive female bodybuilder. *Physician Sportsmed* 1989; 17: 116-25
17. Worth R, Kettelkamp DB, Defalque R, et al. Saphenous nerve entrapment: a cause of medial knee pain. *Am J Sports Med* 1984; 12: 80-1
18. Wartenberg R. Digitalia paraestetica and gonialgia paraestetica. *Neurology* 1953; 4: 106-16
19. Senegor M. Iatrogenic saphenous neuralgia. *Neurosurgery* 1991; 28: 295-8
20. McCrory P, Bell S. Nerve entrapment syndromes as a cause of pain in the hip, groin and buttock. *Sports Med* 1999; 27: 261-74
21. Akyuz G, Us O, Turan B, et al. Anterior tarsal tunnel syndrome. *Electromyogr Clin Neurophysiol* 2000; 40 (2): 123-8
22. Mumenthaler M, Schliack H. Peripheral nerve lesions: diagnosis and therapy. New York: Thieme, 1991

23. Leach R, Purnell M, Saito A. Peroneal nerve entrapment in runners. *Am J Sports Med* 1989; 17: 287-91
24. Moller B, Kadin S. Entrapment of the common peroneal nerve. *Am J Sports Med* 1987; 15: 90-1
25. Stack R, Bianco A, McCarty C. Compression of the common peroneal nerve by ganglion cysts. *J Bone Joint Surg Am* 1965; 47: 773-8
26. Fabre T, Piton C, Andre D, et al. Peroneal nerve entrapment. *J Bone Joint Surg Am* 1998; 80 (1): 47-53
27. Styf J. Entrapment of the superficial peroneal nerve: diagnosis and results of decompression. *J Bone Joint Surg Br* 1989; 71: 131-5
28. Styf J, Korner I. Chronic anterior compartment syndrome of the leg. *J Bone Joint Surg Am* 1986; 68: 1338-47
29. Styf J. Chronic exercise-induced pain in the anterior aspect of the lower leg: an overview of the diagnosis. *Sports Med* 1989; 7: 331-9
30. Levin K, Stevens J, Daube J. Superficial peroneal nerve conduction studies for electromyographic diagnosis. *Muscle Nerve* 1986; 9: 322-6
31. Adelman K, Wilson G, Wolf J. Anterior tarsal tunnel syndrome. *J Foot Surg* 1988; 27: 299-302
32. Parks A. Intraneural ganglion of the lateral popliteal nerve. *J Bone Joint Surg Br* 1961; 43: 784-90
33. Muckart R. Compression of the common peroneal nerve by intramuscular ganglion from the superior tibio-fibular joint. *J Bone Joint Surg Br* 1976; 58: 241-4
34. Evans J, Neumann L, Frostick S. Compression neuropathy of the common peroneal nerve caused by a ganglion. *Microsurgery* 1994; 15: 193-5
35. Kernohan J, Levack B, Wilson J. Entrapment of the superficial peroneal nerve: three case reports. *J Bone Joint Surg Br* 1985; 67: 60-1
36. Styf J, Morberg G. Superficial peroneal tunnel syndrome. *J Bone Joint Surg Br* 1997; 79: 801-7
37. Johnston E, Howell S. Tension neuropathy of the superficial peroneal nerve: associated conditions and response to surgical release. *Foot Ankle Int* 1999; 20 (9): 576-82
38. Daniels T, Lau J, Hearn T. The effects of foot position and load on tibial nerve tension. *Foot Ankle Int* 1998; 19 (2): 73-8
39. Williams D. A study of the human medial peroneal nerve, a new name proposed for the peroneal anastomotic nerve. *Anat Rec* 1954; 118: 415-21
40. Coert J, Dellon A. Clinical implications of the surgical anatomy of the sural nerve. *Plast Reconstr Surg* 1994; 94: 850-5
41. Pringle R, Protheroe K, Mukherjee S. Entrapment neuropathy of the sural nerve. *J Bone Joint Surg Br* 1974; 56: 465-8
42. Schon L. Nerve entrapment, neuropathy and nerve dysfunction in athletes. *Orthop Clin North Am* 1994; 25: 47-59
43. Schuchmann J. Isolated sural neuropathy: report of two cases. *Arch Phys Med Rehabil* 1980; 61: 313-29
44. Aszmann OC, Ebner JM, Dellon AL. Cutaneous innervation of the medial ankle: an anatomic study of the saphenous, sural, and tibial nerves and their clinical significance. *Foot Ankle Int* 1998; 19 (11): 753-6
45. Dellon A, Mackinnon S. Tibial nerve branching in the tarsal tunnel. *Arch Neurol* 1984; 41: 645-6
46. Nagaoka M. An anatomical study of the tarsal tunnel. *Nippon Seikeigeka Gakkai Zasshi* 1990; 64: 208-16
47. Baxter DE, Pfeffer GB. Treatment of chronic heel pain by surgical release of the first branch of the lateral plantar nerve. *Clin Orthop* 1992 Jun; (279): 229-36
48. Campbell P, Lawton JO. Heel pain: diagnosis and management. *Br J Hosp Med* 1994; 52 (8): 380-5
49. Goecker RM, Banks AS. Analysis of release of the first branch of the lateral plantar nerve. *J Am Podiatr Med Assoc* 2000; 90 (6): 281-6
50. Hendrix CL, Jolly GP, Garbalosa JC, et al. Entrapment neuropathy: the etiology of intractable chronic heel pain syndrome. *J Foot Ankle Surg* 1998; 37 (4): 273-9
51. Pfeffer GB. Plantar heel pain. *Instr Course Lect* 2001; 50: 521-31
52. Oh SJ, Kwon KH, Hah JS, et al. Lateral plantar neuropathy. *Muscle Nerve* 1999; 22 (9): 1234-8
53. McMaster WC. How can chronic heel pain be treated? *Postgrad Med* 2001; 109 (4): 137-8
54. Oh SJ, Meyer RD. Entrapment neuropathies of the tibial (posterior tibial) nerve. *Neurol Clin* 1999; 17 (3): 593-615, vii
55. Kashani S, Moon A, Gaunt W. Tibial nerve entrapment by a Baker's cyst. *Arch Phys Med Rehab* 1985; 66: 49-51
56. Donell S, Barrett D. Entrapment neuropathies. Part 2: lower limb. *Br J Hosp Med* 1991; 46: 99-101
57. Nakano K. The entrapment neuropathies. *Muscle Nerve* 1978; 1: 264-79
58. Stewart J. Medial plantar neuropathy. *Neurology* 1981; 31: 149
59. Baxter D. Compressive neuropathies of the foot and ankle. *Oper Tech Sports Med* 1994; 2: 18-23
60. Oh S, Lee K. Medial plantar neuropathy. *Neurology* 1987; 37: 1408-10
61. Fredericson M, Standage S, Chou L, et al. Lateral plantar nerve entrapment in a competitive gymnast. *Clin J Sport Med* 2001; 11 (2): 111-4
62. Hah J, Kim D. Lateral plantar neuropathy: a heretofore unrecognized neuropathy. *Muscle Nerve* 1992; 15: 1175
63. Brooks D. Nerve compression by simple ganglia: a review of thirteen collected cases. *J Bone Joint Surg Br* 1952; 34: 391-400
64. Cerciello M, Napoleoni F. The tarsal tunnel syndrome [in Italian]. *Riv Eur Sci Med Farmacol* 1991; 13 (1-2): 61-9
65. Trepman E, Kadel N, Chisholm K, et al. Effect of foot and ankle position on tarsal tunnel compartment pressure. *Foot Ankle Int* 1999; 20 (11): 721-6
66. Marinacci A. Neurological syndromes of the tarsal tunnels. *Bull Los Angeles Neurol Soc* 1968; 33: 90-100
67. Edwards W, Lincoln C, Basset F. The tarsal tunnel syndrome: diagnosis and treatment. *JAMA* 1969; 207: 716-20
68. Keck C. The tarsal tunnel syndrome. *J Bone Joint Surg Am* 1962; 44: 180-2
69. Linscheid R, Burton R, Fredericks E. Tarsal tunnel syndrome. *South Med J* 1970; 63: 1313-23
70. Pace N, Serafini P, LoIocano E, et al. The tarsal and calcaneal tunnel syndromes. *Ital J Orthop Traumatol* 1991; 17: 247-52
71. Jackson D, Haglund B. Tarsal tunnel syndrome in athletes: case reports and literature review. *Am J Sports Med* 1991; 19: 61-5
72. Jackson D, Haglund B. Tarsal tunnel syndrome in runners. *Sports Med* 1992; 13: 146-9
73. Park TA, Del Toro DR. Electrodiagnostic evaluation of the foot. *Phys Med Rehabil Clin N Am* 1998; 9 (4): 871-96, vii-viii

74. Johnson E, Ortiz P. Electrodiagnosis of tarsal tunnel syndrome. *Arch Phys Med Rehabil* 1966; 47: 776-80
75. Fu R, DeLisa J, Kraft G. Motor nerve latencies through the tarsal tunnel in normal adult subjects. *Arch Phys Med Rehabil* 1980; 61: 243-8
76. David WS, Doyle JJ. Segmental near nerve sensory conduction studies of the medial and lateral plantar nerve. *Electromyogr Clin Neurophysiol* 1996; 36 (7): 411-7
77. de Bisschop G, Claparede P, Bence YR, et al. Neuromuscular study of the foot: value of electromyographic and neurographic examinations [in French]. *Electrodiagn Ther* 1979; 16 (2): 77-86
78. Zeiss J, Ebraheim N, Rusin J. Magnetic resonance imaging in the diagnosis of tarsal tunnel syndrome: case report. *Clin Imaging* 1990; 14: 123-6
79. Frey C, Kerr R. Magnetic resonance imaging and the evaluation of tarsal tunnel syndrome. *Foot Ankle* 1993; 14 (3): 159-64
80. Cheung YY, Rosenberg ZS, Colon E, et al. MR imaging of flexor digitorum accessorius longus. *Skeletal Radiol* 1999; 28 (3): 130-7
81. Rosenberg ZS, Beltran J, Bencardino JT. From the RSNA Refresher Courses. Radiological Society of North America: MR imaging of the ankle and foot. *Radiographics* 2000; 20 Spec. No.: S153-79
82. Carrel JM, Davidson DM, Goldstein KT. Observations on 200 surgical cases of tarsal tunnel syndrome. *Clin Podiatr Med Surg* 1994; 11 (4): 609-16
83. Ward PJ, Porter ML. Tarsal tunnel syndrome: a study of the clinical and neurophysiological results of decompression. *J R Coll Surg Edinb* 1998; 43 (1): 35-6
84. Davis A, Schon L. Branches of the tibial nerve: anatomic variations. *Foot Ankle Int* 1995; 16: 21-9
85. De Palma L, Tulli A. Morton's disease: optic and electron microscopy observations [in French]. *Acta Orthop Belg* 1991; 57 (3): 285-95
86. Lassmann G, Lassmann H, Stockinger L. Morton's metatarsalgia: light and electron microscopic observations and their relation to entrapment neuropathies. *Virchows Arch* 1976; 370: 307-21
87. Falck B, Hurme M, Hakkarainen S. Sensory conduction velocity of plantar digital nerves in Morton's metatarsalgia. *Neurology* 1984; 34: 698-701
88. Oh S, Kim H, Ahmad B. Electrophysiological diagnosis of interdigital neuropathy of the foot. *Muscle Nerve* 1984; 7: 218-115
89. Redd R, Peters V, Emery S, et al. Morton's neuroma: sonographic evaluation. *Radiology* 1989; 171: 415-6
90. Bennett GL, Graham CE, Mauldin DM. Morton's interdigital neuroma: a comprehensive treatment protocol. *Foot Ankle Int* 1995; 16 (12): 760-3
91. Greenfield J, Rea J, Ilfeld F. Morton's interdigital neuroma: indications for treatment by local injections versus surgery. *Clin Orthop* 1984; 185: 142-4
92. Gaynor R, Hake D, Spinner S, et al. A comparative analysis of conservative versus surgical treatment of Morton's neuroma. *J Am Podiatr Assoc* 1989; 79: 27-30
93. Dellon AL. Treatment of Morton's neuroma as a nerve compression: the role for neurolysis. *J Am Podiatr Med Assoc* 1992; 82 (8): 399-402
94. Nashi M, Venkatachalam AK, Muddu BN. Surgery of Morton's neuroma: dorsal or plantar approach? *J R Coll Surg Edinb* 1997; 42 (1): 36-7
95. Still GP, Fowler MB. Joplin's neuroma or compression neuropathy of the plantar proper digital nerve to the hallux: clinicopathologic study of three cases. *J Foot Ankle Surg* 1998; 37 (6): 524-30
96. Ames P, Lenet M, Sherman M. Joplin's neuroma. *J Am Podiatr Assoc* 1980; 70: 99-101
97. Joplin R. The proper digital nerve, vitallium stem arthroplasty and some thoughts about foot surgery in general. *Clin Orthop* 1971; 76: 199-212
98. Merritt G, Subotnick S. Medial plantar digital proper nerve syndrome (Joplin's neuroma): typical presentation. *J Foot Surg* 1982; 21: 166-9
99. Jordan B, Tsaris P, Warren R, editors. *Sports neurology*. 2nd ed. Philadelphia (PA): Lippincott-Raven Publishers, 1998
100. Bell S. Partial compartment fasciectomy as treatment for failed anterior compartment decompression. *J Bone Joint Surg Br* 1986; 68: 815-7

---

Correspondence and offprints: Dr *Paul McCrory*, Olympic Park Sports Medicine Centre, Swan Street, Melbourne, VIC 3004, Australia.

E-mail: pmccrory@compuserve.com