

Nerve Entrapment Syndromes as a Cause of Pain in the Hip, Groin and Buttock

Paul McCrory¹ and Simon Bell²

1 Department of Neurology, Olympic Park Sports Medicine Centre, Melbourne, Victoria, Australia

2 Department of Orthopaedics, Olympic Park Sports Medicine Centre, Melbourne, Victoria, Australia

Contents

Abstract	261
1. Neurological Causes of Hip and Groin Pain	262
2. Clinical Features of Nerve Entrapment Syndromes	262
3. Specific Nerve Entrapment Syndromes	262
3.1 Iliohypogastric Nerve	262
3.2 Ilioinguinal Nerve	263
3.3 Genitofemoral Nerve	264
3.4 Obturator Nerve	266
3.5 Lateral Cutaneous Nerve of the Thigh	267
3.6 Femoral Nerve	268
3.7 Pudendal Nerve	268
3.8 Posterior Cutaneous Nerve of the Thigh (PCNT)	268
3.9 Superior and Inferior Gluteal Nerves	269
3.10 Sciatic Nerve	270
3.11 The 'Piriformis Syndrome'	270
4. Investigation of Sport-Related Nerve Entrapment Syndromes	272
5. Treatment of Sport-Related Nerve Entrapment Syndromes	273
6. Conclusion	273

Abstract

In sports medicine, chronic hip, groin and buttock pain is a common diagnostic problem. Because of the complex anatomy of this region and the many potential neurological causes for pain, few sports clinicians have a detailed understanding of this problem. This paper discusses the clinical aspects of nerve entrapment syndromes related to sport and takes a regional approach in order to provide a diagnostic framework for the general sports physician. The various neurological syndromes are discussed and the surgical management elaborated in detail.

For some specific conditions, such as the so-called 'piriformis syndrome', the pathophysiological understanding has changed since the early descriptions and now this particular diagnosis is often ascribed to almost any cause of buttock and/or hamstring symptoms. We discuss the nature of the origin of local symptoms and note that the often described symptoms are more likely due to compression of structures other than the sciatic nerve. Furthermore, the role of piriformis

hypertrophy or anatomical nerve variations in the genesis of this syndrome must be questioned. We suggest renaming this the 'deep gluteal syndrome' to account for all of the observed phenomena.

As sports medicine continues to develop a scientific basis, the role of nerve entrapments as the basis for chronic symptomatology is undergoing a new understanding and clinicians need to be aware of the diagnostic possibilities and be able to advise patients accordingly on the basis of scientific fact not anecdotal fiction.

Chronic hip, groin and buttock pain is a common presentation of sporting injury and accounts for approximately 10% of all attendances to sports medicine clinics worldwide.^[1-5] Because of the complex anatomical arrangements in this region, the diagnosis of chronic groin or pelvic pain in athletes often remains elusive. Clinicians may be frustrated by a lack of scientific evidence for the various pathological diagnoses that are anecdotally reported in the sporting literature.^[6]

This paper focuses on the neurological causes of hip, groin and buttock pain, in particular the various nerve entrapment syndromes. Although nerve entrapment syndromes represent a relatively small group of conditions causing such problems in athletes, they are nevertheless important because a precise pathological diagnosis may be made and definitive management instituted.

1. Neurological Causes of Hip and Groin Pain

There are a variety of potential neurological causes for pain in the hip and groin apart from focal peripheral nerve entrapments.^[7-13] These include radicular pain arising from irritation of the upper lumbar nerve roots, referred pain from innervated spinal structures and the chronic regional pain syndromes. These entities will not be further discussed in this paper. In addition, the clinician must also be aware that a number of non-neurological disease processes and soft tissue injuries also may present with similar symptoms and may need to be excluded by the appropriate investigational strategies.

The anatomical possibilities for the nerve entrapment syndromes in this region arise from the lumbosacral plexus and its branches (fig. 1.)

2. Clinical Features of Nerve Entrapment Syndromes

Unless nerve entrapment syndromes produce 'hard' neurological signs of motor weakness, sensory loss or change in tendon reflexes, specific diagnosis may be difficult and often circumstantial. This is particularly true of nerve entrapments around the pelvis where the cutaneous sensory dermatomes overlap considerably and many of the nerves have no motor innervation which can be easily tested. For this reason, a regional approach to the likely nerve entrapments may be useful and then the appropriate electrophysiological studies sought.

A summary of the nerves and their motor and sensory distribution where it relates to the hip, groin and buttock region is set out in table I. Details of the individual nerves are provided in section 3 (table I).

It must be emphasised that many nerve entrapment syndromes may present with nonspecific or poorly localised pain rather than hard neurological signs, at least in the early stages of the condition. It is for this reason that a regional view of the site of pain may be useful for the clinician in attempting to pin down the nerve responsible for the symptoms. See table II and figures 2, 3 and 4. However, it must be emphasised that the cutaneous dermatomal distribution is extremely variable between individuals, and the stylised approach set out in these figures should be seen as a general guide only.

3. Specific Nerve Entrapment Syndromes

3.1 Iliohypogastric Nerve

3.1.1 Anatomy

The iliohypogastric nerve (IHN) is a branch of

the lumbar plexus arising from the primary ventral rami of L1 and L2. The nerve passes through the psoas muscle and then curves downward, passing behind the lower pole of the kidney. Approximately halfway between the anterior superior iliac spine (ASIS) and the highest point of the iliac crest, the nerve pierces the muscles of the abdominal wall giving off muscular branches and then continues its course following the line of the iliac crest, finally dividing into the lateral and anterior cutaneous branches near the ASIS. The lateral cutaneous branch crosses the iliac crest to innervate a patch of skin in the upper buttock, whereas the anterior cutaneous branch courses just above the inguinal ligament to supply a small area of skin above the pubis (see figures 2, 3 and 4).

3.1.2 Aetiology

Disorders of this nerve and its 2 branches are relatively rare.^[9] The main trunk of this nerve can be damaged by retroperitoneal tumours or large surgical incisions (e.g. for nephrectomies).^[12] Damage to the main nerve trunk produces sensory abnormalities in the distribution of the nerve and bulging of the muscles of the lower quadrant of the abdomen. The anterior branch of this nerve may be damaged by surgical incisions in the lower quadrant of the abdomen.^[14] The resulting suprapubic sensory deficit is usually trivial, although some patients report a neuralgic pain. The lateral branch can be compressed where it crosses the iliac crest giving rise to an isolated sensory disturbance over the upper buttock.^[12]

In sports medicine, the likely causes of injury are either from regional surgery or from direct trauma to the lateral pelvis, an injury common to all collision sports. The relationship of injuries to this nerve and the lower abdominal bulging that is reported as part of a 'footballers hernia' is unclear but should be excluded in athletes before proceeding to surgical herniorrhaphy.

3.1.3 Treatment

Where the IHN neuralgia is thought to be secondary to previous surgical trauma and scarring, then exploration of the surgical scar and neurolysis or excision of the damaged nerve is performed.

3.2 Ilioinguinal Nerve

3.2.1 Anatomy

The ilioinguinal nerve (IIN) is a branch of the lumbar plexus arising from the L1 and L2 ventral rami. The nerve passes through the psoas and then follows a similar course to the IHN. Adjacent to the ASIS, muscular branches supply the lowermost portions of the transversalis and internal oblique muscles, and a branch passes posteriorly to innervate a strip of skin over the iliac crest. The rest of the nerve enters the inguinal canal and then divides into its terminal branches that supply the skin over the inguinal ligament, the upper medial thigh, and the base of the penis and upper part of the scrotum in men or the mons pubis and labium majus in women.

3.2.2 Aetiology

Lesions of this nerve are best considered anatomically following the course of the nerve. Prox-

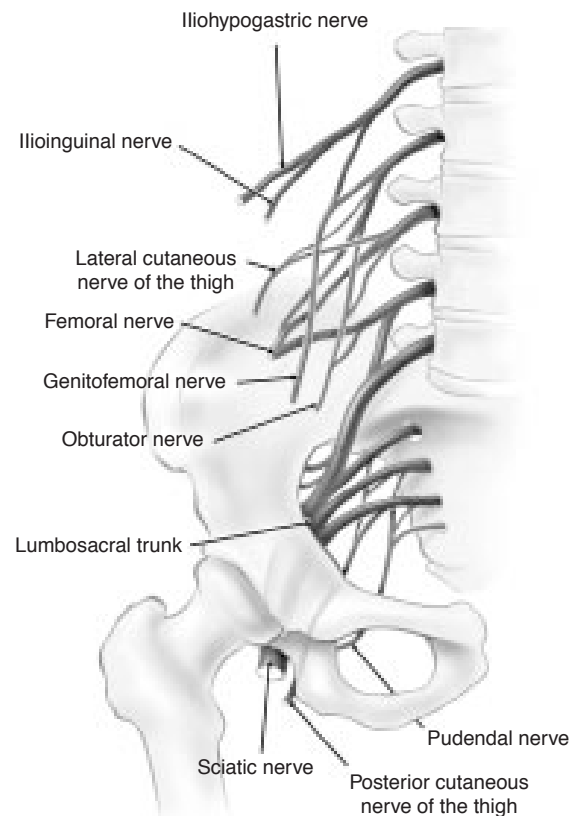


Fig. 1. Diagrammatic anatomy of the lumbosacral plexus.

Table I. Motor and sensory distribution of the lumbosacral plexus^[9]

Nerve	Motor innervation	Cutaneous sensory distribution
Iliohypogastric nerve	Abdominal wall muscles	Upper buttock Suprapubic
Ilioinguinal nerve	Internal oblique, transversalis	Inguinal ligament Upper medial thigh Lateral scrotal skin or mons/labia
Genitofemoral nerve	Nil	Anterior thigh Lateral scrotal skin or mons/labia
Obturator nerve	Adductor longus and brevis gracilis, pectineus, adductor magnus, obturator externus	Distal medial thigh, knee joint (hip joint)
Femoral nerve	Quadriceps muscle	Anterior thigh
Lateral cutaneous nerve of the thigh	Nil	Anterolateral thigh
Sciatic nerve	Hamstring muscles	Nil in this region
Pudendal nerve	External anal sphincter, perineal muscles, external urethral sphincter	Perineal skin, scrotal or labial skin, perianal skin
Superior and inferior gluteal nerves	Gluteus medius, minimus and maximus, tensor fascia latae	Nil
Posterior cutaneous nerve of the thigh	Nil	Lower buttock, posterior thigh, perineum

imally, nerve lesions may occur with surgical incisions. Entrapment has also been reported where the nerve passes through the muscles of the abdominal wall medial to the ASIS.^[11,15] The clinical triad of pain in the right inguinal region radiating into the genitals, sensory abnormalities in the distribution of the nerve and tenderness on palpation 2 to 3cm medial to and below the ASIS should suggest involvement of this nerve.^[16] Ilioinguinal neuropathy may also develop after a normal pregnancy because of entrapment in the muscular layers caused by stretching of the abdominal wall.^[17,18] Nerve injury may also occur during bone harvesting from the iliac crest and from blunt nonsurgical trauma to the lateral abdominal wall.^[19-21]

The most common cause of inguinal neuropathy appears to be damage to the nerve during surgical operations such as appendectomy, herniorrhaphy, hysterectomy and the treatment of stress incontinence in women.^[9,14,22-28] Given the frequency of these operations, such damage occurs surprisingly seldom, but when it does occur it can be particularly troublesome. Other pathology in the inguinal canal that compress neural structures include tumours and endometriosis.^[26] In sports medicine, the same diagnostic considerations apply as for the IHN.

3.2.3 Treatment

The problem of neuralgia or entrapment of this nerve will be considered together with the genitofemoral nerve (GFN) [section 3.3], as both may occur following surgery to this region and may be difficult to differentiate on clinical grounds.

3.3 Genitofemoral Nerve

3.3.1 Anatomy

The GFN arises from the ventral rami of the L1 and L2 spinal nerve roots and passes through the psoas, emerging on its anterior aspect. The nerve then descends retroperitoneally until it reaches the inguinal ligament, where it divides into the genital and femoral branches. The genital branch enters the inguinal canal and then shares in sensory supply of the scrotal skin or the mons pubis and labium majus. The femoral branch passes under the inguinal ligament to supply a small patch of skin on the anterior thigh (figs. 2a, b and c).

3.3.2 Aetiology

The most common reported causes of entrapment of the GFN relate to surgical trauma.^[22,25,26,29-31] Other rare case reports include wearing tight clothing and direct trauma to the groin resulting in local scarring.^[30,32,33] Spontaneous entrapment of the

nerve has not been described. In our experience, all sport-related cases have followed surgical operations to this region.

3.3.3 Treatment

As previously mentioned in section 3.2.3, it is often difficult to accurately separate GFN and IIN nerve lesions on clinical grounds. Their cutaneous sensory distribution commonly overlaps and there are no specific distinguishing tests of motor function. If surgery is contemplated, then diagnostic local anaesthetic blocks may be performed to assist in diagnosis. The IIN may be blocked by infiltrating local anaesthetic medial to the ASIS in the muscular layers of the anterior abdominal wall. If an IIN block does not relieve the symptoms but a block of the L1/2 nerve roots does then exploration of the GFN should be the first surgical approach. If the blocks are inconclusive or provide only partial relief of symptoms then consideration should

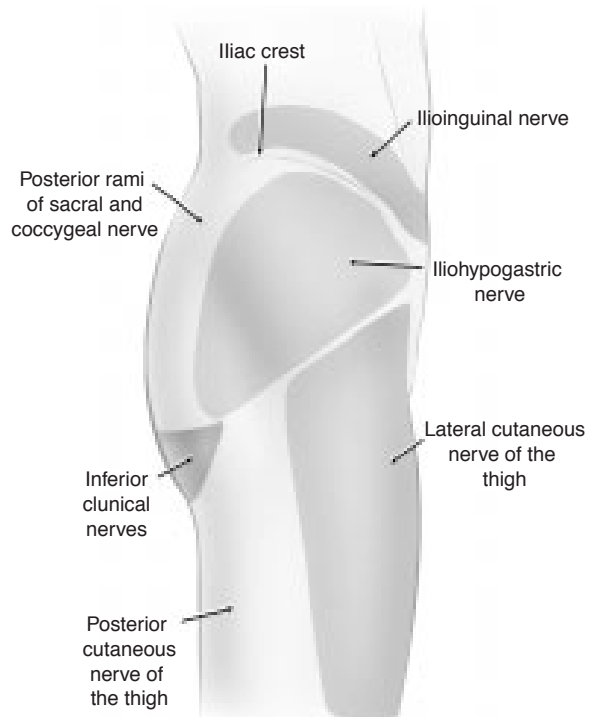


Fig. 2. Cutaneous sensory innervation of the hip, groin and buttock – lateral view.

Table II. Regional approach to nerve entrapment syndromes

Region	Subregion	Nerve
Anterior	Inguinal	Ilioinguinal nerve
		Genitofemoral nerve
		Iliohypogastric nerve
		T11/T12/L1 nerve root
	Suprapubic	Genitofemoral nerve
		Iliohypogastric nerve
Thigh	Lateral cutaneous nerve of thigh	
	Genitofemoral nerve	
	Femoral nerve	
	Obturator nerve	
Lateral	Buttock	Ilioinguinal nerve
		Iliohypogastric nerve
		Lateral cutaneous nerve of thigh
	Thigh	T12 root
		Lateral cutaneous nerve of thigh
		Posterior cutaneous nerve of thigh
Posterior	Buttock	Posterior rami of the lumbar, sacral and coccygeal nerves
		Iliohypogastric nerve
		Lateral cutaneous nerve of thigh
		Posterior cutaneous nerve of thigh
		T12 root
		Lateral cutaneous nerve of thigh
		Posterior cutaneous nerve of thigh
		Inferior medial and lateral clunical nerves

be given to staged surgical exploration of both nerves.^[22,26,29]

When surgically approaching the IIN, exploration of the previous inguinal incision, identification of the IIN and either neurolysis or a neurectomy of the proximal part of the nerve including the entrapped segment should be performed.

When approaching the GFN, a transverse flank incision should be used similar to that of a lumbar sympathectomy. This is because once the GFN passes into the inguinal region its branches are too small to be precisely identified. The muscles of the abdominal wall are muscles divided as necessary. The retroperitoneum is then exposed and the psoas muscle and ureter identified. The GFN can be identified as it pierces the psoas muscle, usually as a single trunk along the medial aspect. The nerve can either be followed distally or divided at this point.

Following division of both nerves, hypoesthesia of the scrotum (or labium majus) and the skin over the femoral triangle as well as loss of the

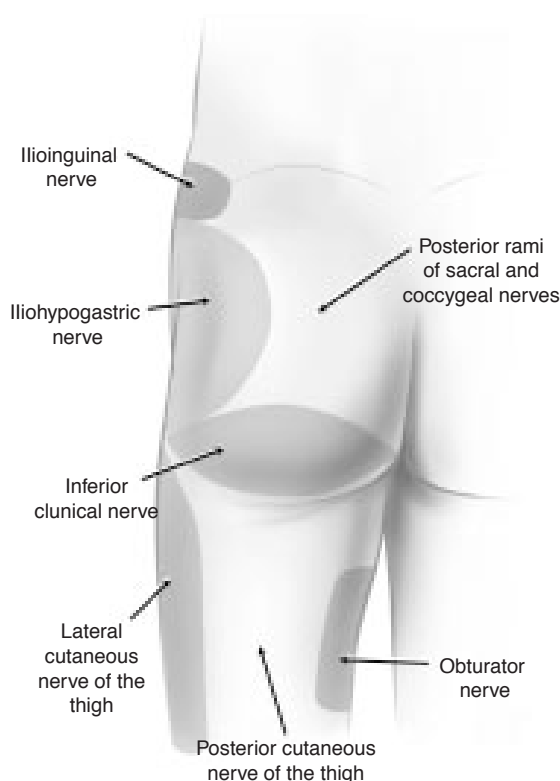


Fig. 3. Cutaneous sensory innervation of the hip, groin and buttock – posterior view.

cremasteric reflex are the main adverse effects. The success rate of surgical exploration of these nerves ranges from 60% for the GFN to 90% for the IIN.^[22]

3.4 Obturator Nerve

3.4.1 Anatomy

The obturator nerve (ON) arises from the ventral rami of L2, 3 and 4 and descends through the psoas passing into the lesser pelvis. The nerve passes through a fibro-osseous tunnel under the pubic ramus. Within the tunnel, the nerve divides into 2 main branches (anterior and posterior) as well a branch to the obturator externus. The anterior branch supplies the adductor longus, brevis and gracilis and, occasionally, pectineus. Its cutaneous division provides the innervation of the skin and fascia of the distal two-thirds of the medial thigh. The posterior branch supplies the adductor magnus and obturator externus. Its sensory division de-

scends to supply the articular capsule, cruciate ligaments and synovial membrane of the knee joint. An inconstant accessory ON may be present which supplies the pectineus and gives hip joint sensation when present.^[34]

3.4.2 Aetiology

The course of the ON places it at risk from compression within the pelvis as well as within the obturator tunnel. The nerve may be compressed within the true pelvis from pelvic fractures, pelvic haematomas, retroperitoneal masses and intrapelvic tumours. Normal life events such as pregnancy can develop complications that lead to obstetrical ON palsy.^[35] While in the obturator tunnel, the nerve is well protected from direct trauma; however, complications of gynaecological or orthopaedic surgery may directly traumatise the nerve.^[36,37] In a single case report,^[11] Kopell and Thompson described obturator tunnel syndrome related to inflammatory changes in the adjacent pubic bone in osteitis pubis. Recently, a series of 32 sport-related cases were reported where the entrapment was related to a fascial band compressing the nerve at the distal exit of the obturator canal.^[7,8] Our experience of this condition now extends to over 150 surgically treated patients.

Other diagnostic possibilities compressing the nerve include obturator herniae. This entity is rare and difficult to diagnose but may respond to surgical intervention.^[38,39]

3.4.3 Treatment

The surgical management of ON entrapment has been well described.^[7] An oblique incision is made in the upper adductor region 2cm distal to the inguinal ligament. The interval between pectineus and adductor longus is then identified and the overlying fascia divided. There are sometimes overlying vessels in this region which require diathermy. The 2 muscles are split by blunt dissection. The anterior branch of the ON is then identified as it passes over adductor brevis. The vessels are divided and the overlying fascia split along the entire visualised course of the nerve. The obturator foramen patency is then assessed digitally and enlarged if necessary.

3.5 Lateral Cutaneous Nerve of the Thigh

3.5.1 Anatomy

The lateral cutaneous nerve of the thigh (LCNT) arises from the lumbar plexus by fusion of the dorsal divisions of the ventral primary rami of the L2 and L3 spinal nerves. The nerve passes retroperitoneally through the psoas and over the iliacus muscle, and emerges under the lateral end of the inguinal ligament through a small tunnel formed by a split in the lateral attachment of the inguinal ligament to the ASIS.^[40] Just distal to the ligament, the LCNT crosses the proximal end of the sartorius muscle, where it divides into anterior and posterior branches that pierce the fascia lata and innervate the skin of the anterolateral aspect of the thigh^[41,42] (figures 2, 3 and 4).

3.5.2 Aetiology

Injury to the LCNT produces the syndrome of meralgia paraesthetica. In most patients, there is no identifiable cause and the nerve is thought to be compressed or kinked as it goes through, under or over the inguinal ligament. Autopsy studies demonstrate neuropathological lesions of the nerve at this site in approximately 50% of cases.^[40,43] Many other associations, including rapid bodyweight change, childbirth and ascites, remain anecdotal. In sport, where local soft tissue trauma to the upper anterolateral thigh is common, the potential exists for injury to this nerve. Female gymnasts commonly report injuries to this nerve secondary to the repetitive trauma of uneven bar work.^[44] Another common sport-related cause of this syndrome is seen in scuba divers where the weight belt directly traumatises the nerve and results in symptoms.

3.5.3 Treatment

It has been reported that many cases of meralgia paraesthetica resolve spontaneously with time.^[45] In a large series, Williams and Trzil reported a 90% resolution rate with conservative therapy.^[40] In persistent or particularly symptomatic cases surgery may be of benefit. The first reported surgical exploration of this nerve was by Harvey Cushing in 1900.^[46]

When considering surgical treatment for this condition, controversy exists as to the optimal procedure. The 2 main options are either neurolysis or transection of the LCNT.^[47] Although transection has been reported to have a better outcome in terms of symptom resolution (95 vs 30 to 80%), the main problem is hypoaesthesia of the anterolateral thigh.^[47]

The transection operation involves an intrapelvic exploration of the nerve. An oblique incision is made 2cm distal to the area of tenderness at the pelvic exit. The nerve is then identified and traced back to the pelvic exit. The nerve is then pulled distally and sectioned so that the proximal end withdraws back into the pelvis. Where multiple branches exist at this level, all must be sectioned as above.

Surgical neurolysis is usually performed through a suprainguinal approach. A horizontal skin incision is made parallel to and 1cm above the inguinal

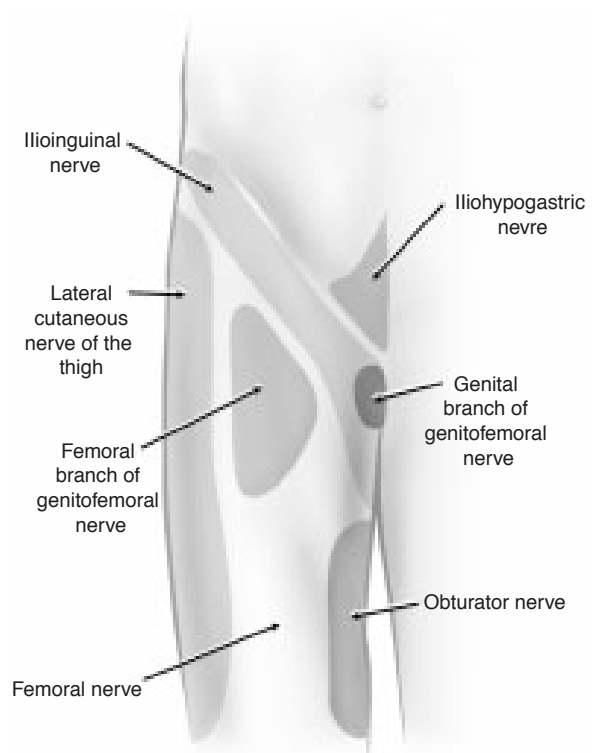


Fig. 4. Cutaneous sensory innervation of the hip, groin and buttock – anterior view.

ligament and medial to the ASIS. The muscles of the abdominal wall are split into layers and the nerve trunk is identified between the iliac fascia. Lysis of fascial bands over the nerve can then be performed and the dissection carried into the thigh. The nerve can also be transposed to a more medial position to relieve any angulation if present.^[48,49]

3.6 Femoral Nerve

3.6.1 Anatomy

The femoral nerve (FN) arises from the lumbar plexus within the psoas and is formed from the posterior divisions of the ventral rami of the L2, 3 and 4 spinal nerves. Emerging from the lateral border of the psoas, it passes under the iliacus fascia and descends along this muscle passing under the inguinal ligament, lateral to the femoral artery and vein. In the upper thigh, it divides into branches to the quadriceps muscles as well as the sensory branches to the skin of the anterior thigh.

The saphenous nerve is the entirely sensory continuation of the FN. It descends in the subsartorial canal alongside the femoral artery and emerges from the canal by piercing a fascial layer about 10cm above the knee. It gives off the infrapatellar branch that supplies the skin over the knee and the remainder of the nerve descends along the medial side of the tibia to end on the inner side of the foot. The main sensory branch, the saphenous nerve, innervates the skin of the medial and anterior surfaces of the knee, and the medial aspect of the lower leg, ankle and arch of the foot.

3.6.2 Aetiology

There are numerous cause of injuries to the FN. These include surgical trauma, abdominal tumours, childbirth, pelvic fractures, iatrogenic trauma and blunt injuries. There are also a number of other nontraumatic causes such as diabetes mellitus, paraneoplastic syndromes and mononeuritis multiplex.^[50-52] An idiopathic femoral neuropathy occurs, but this is usually seen in men over 50 years of age and complete recovery usually follows within a matter of weeks. In sports medicine, the most common injury affecting this nerve is a psoas bursitis or strain of the iliopsoas muscle with associ-

ated haematoma and swelling. These pathologies may cause irritation of the nerve producing the characteristic pattern of pain and sensory loss.

3.6.3 Treatment

Even in patients who clinically appear to have an obvious FN entrapment, we have found it difficult to localise the site of the lesion and generally found surgical exploration of the nerve to be unrewarding unless focal pathology is present.

3.7 Pudendal Nerve

3.7.1 Anatomy

The pudendal nerve (PN) is the principal nerve of the perineum arising from the ventral rami of S2, 3 and 4 which passes through the sciatic notch and then runs deep to the sacrospinous ligament and into the perineal area. Its first branch is the inferior rectal (or haemorrhoidal) nerve that innervates the external anal sphincter and contains sensory fibres from the lower anal canal and perianal skin. The next branch, the perineal nerve, supplies the muscles of the perineum, the erectile tissue of the penis, the external urethral sphincter and the skin of the perineum, scrotum or labia. The final branch of the PN is the dorsal nerve of the penis or clitoris (fig. 5).

3.7.2 Aetiology

Direct injuries to this nerve are rare because it is so deeply situated. It is occasionally reported to be damaged by deep buttock injections, prolonged childbirth, surgical manipulation and pelvic fractures.^[53,54] Cyclists may also compress this nerve with prolonged riding which results in sensory loss or impotence in severe cases.^[55,56]

3.7.3 Treatment

Surgical exploration of this nerve is best performed by urologists or gynaecological surgeons experienced in the complex anatomy of this region. Readers are referred to specialist texts books in this area.^[57]

3.8 Posterior Cutaneous Nerve of the Thigh (PCNT)

3.8.1 Anatomy

The posterior cutaneous nerve of the thigh (PCNT) arises from the ventral rami of S1, 2 and 3.

The nerve passes through the sciatic notch below the piriformis and then passes superficially down the back of the thigh to the knee. It supplies the sensation to the skin of the lower buttock and posterior thigh. It also gives rise to perineal branches (the cluneal or clunical nerves) that innervate the skin of the perineum and scrotum or labia together with branches from the PN (fig. 5).

3.8.2 Aetiology

Isolated lesions of this nerve are said to be rare and may be due to iatrogenic trauma, falls onto the buttock, pressure from prolonged bicycle riding and tumours in the presacral region which compress the nerve in its intrapelvic course.^[9] It has also been reported that some cases may be secondary to pressure from the distal edge of gluteus maximus as a result of prolonged sitting.^[58] As discussed in section 3.11, this nerve may be responsible for many of the symptoms ascribed to the sciatic nerve in the so-called 'piriformis syndrome'.

3.8.3 Treatment

The surgical exploration of this nerve in the buttock is the same as for the sciatic nerve described in section 3.10.

3.9 Superior and Inferior Gluteal Nerves

3.9.1 Anatomy

The superior and inferior gluteal nerves (SGNs and IGNs) arise from the sacral plexus and pass through the sciatic notch into the deep gluteal region along with the sciatic nerve, PN and the PCNT. The SGN which arises from L4, L5 and S1, passes above the piriformis muscle to enter the deep gluteal region and supplies the gluteus medius, gluteus minimus and tensor fascia lata muscles. The IGN arises from L5, S1 and S2, passes below the piriformis muscle and supplies the gluteus maximus. These nerves have no cutaneous sensory distribution (fig. 5).

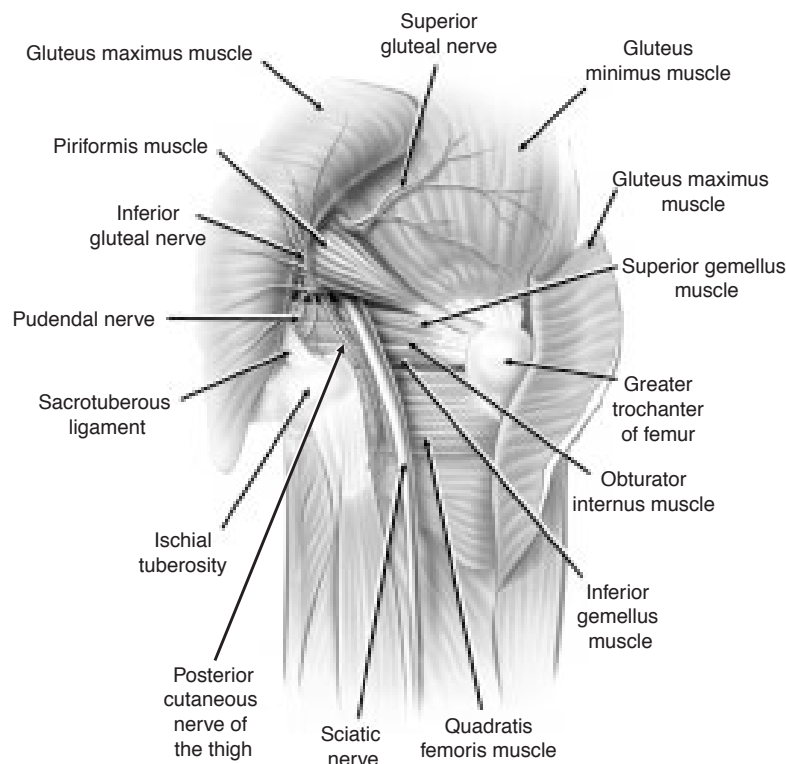


Fig. 5. Anatomy of the deep gluteal region.

3.9.2 Aetiology

Injuries to the SGN are rare but have been reported after local buttock trauma, pelvic fractures, hip surgery and after buttock injections.^[59-61] Because of its separate course above the piriformis, injuries to this nerve may occur in isolation from other deep gluteal nerves. The IGN is usually injured in variable combination with the other nerves exiting below piriformis namely the sciatic, PN and PCNT. The role of piriformis hypertrophy as the compressive structure in producing this condition is controversial.^[62] However, local trauma or space occupying lesions involving this nerve in isolation have been reported.^[63]

3.9.3 Treatment

Where postsurgical or traumatic lesions of these nerves are present, then spontaneous resolution has been reported.^[64] Surgical exploration of the nerves are similar to the sciatic approach described in section 3.10.

3.10 Sciatic Nerve

3.10.1 Anatomy

The sciatic nerve is the major nerve arising from the lumbosacral plexus, originating from the ventral rami of L4 to S3 inclusive. The nerve root contributions fuse to form a single trunk within the pelvis and then exits through the sciatic notch inferior to the piriformis muscle. Rarely, the nerve may pass through or over this muscle.^[13] Within the deep gluteal region, the nerve passes between the ischial tuberosity and the greater trochanter of the femur lying close to the posterior capsule of the hip joint and is covered at that point by the gluteus maximus muscle. The nerve trunk passes distally deep in the thigh to the popliteal fossa where it divides into its 2 terminal branches – the tibial and peroneal nerves. The sciatic nerve innervates the hamstring group of muscles. No cutaneous sensory branch arise from the sciatic nerve trunk (fig. 5).

3.10.2 Aetiology

Sciatic trunk neuropathies may occur at any anatomical level from the abdomen to the knee. In the deep gluteal region, local trauma, pelvic fractures, hip fractures and dislocations, hip joint surgery or

space occupying lesions may compress the nerve.^[9] The specific entity of the ‘piriformis syndrome’ will be discussed in detail in section 3.11. A particular form of sciatic nerve entrapment has been reported in sport where the nerve becomes entrapped at the level of the ischial tuberosity at the attachment of the biceps femoris muscle by either a fibrous aponeurotic band or a fibrous edge to that muscle. Surgical division of this fibrous structure cured the symptoms in the series of cases described by Puranen and Orava.^[65]

3.11 The ‘Piriformis Syndrome’

The ‘piriformis syndrome’ (PFS) has been described as a form of sciatic nerve entrapment causing buttock and hamstring pain. In sports medicine practice, where chronic hamstring pain is a common diagnostic problem, this syndrome is often put forward as a possible cause to explain these symptoms.

The original description of this condition dates from 1928 when Yeoman stated that insufficient attention had been paid to the piriformis muscle as a potential cause of sciatica.^[66] Subsequently, clinical and anatomical studies were reported, developing the nature of this condition further. In 1934, Freiberg and Vinkle reported surgical division of the piriformis muscle as a cure for sciatica.^[67] Interestingly, although the original descriptions of this putative syndrome related to the distal sciatic symptoms, in recent times the term has been utilised more nonspecifically to include buttock and hamstring pain alone without focal neurological signs.^[1]

3.11.1 Anatomy

The piriformis muscle arises from the pedicles of the 2nd to 4th sacral segments and the adjacent portion of the bone lateral to the sacral foramina. There is also a fascial origin arising from the capsule of the sacroiliac joint and whose fibres pass inferiorly rather than laterally. Therefore, it is in contact with the anterior ligament of the sacroiliac joint and the roots of the 1st to 3rd sacral nerves. Its lower border is closely related to the trunk of

the sciatic nerve and to the gemelli and the obturator internus muscles.^[9,13]

3.11.2 Clinical Findings

In the sports medicine literature, the PFS is usually described as a cramping or aching pain in the buttock and/or hamstring. It may be described as a sensation that the hamstring muscles feel 'tight' or are about to tear. Physical examination demonstrates that the buttock pain is exacerbated by hip flexion movements combined with involving active hip external rotation or passive internal rotation as well as hip flexion. Local muscle spasm is usually palpable in the obturator internus and/or piriformis muscles. Neurological examination is usually normal. Biomechanical assessment of the hip and lower leg usually demonstrates restricted hip external rotation and lumbosacral muscle tightness.^[1]

3.11.3 Investigation

There have been few reports of appropriate investigational approaches to this problem. Imaging modalities have generally been disappointing. Electrodiagnostic tests may provide the most simple and practical means of diagnosis. Long latency delayed potentials (e.g. F and H waves) are normal at rest but may become delayed in manoeuvres where the piriformis and the hip external rotators are tightened (e.g. by passive internal rotation and hip flexion).^[68] Similarly short latency somatosensory evoked potentials have been reported to be of use in diagnosis.^[69] The electromyogram (EMG) is usually normal, unless severe longstanding compression has led to denervation changes in the muscle.

3.11.4 Treatment

Once a diagnosis has been made, the treatment usually depends on the suspected pathology. If muscular spasm and tightness is the suspected aetiology then an aggressive stretching and massage programme should be instituted. If this is initially unsuccessful, a local anaesthetic block to the muscle should be considered. If conservative methods fail then surgical neurolysis should be contemplated.

Before considering surgery for this condition it is important to accurately localise, as far as possible, the site of sciatic nerve entrapment. In most cases, this will be at the level of the piriformis although the 'hamstring syndrome' may mimic the symptoms. It is impossible to decompress both regions easily through a single incision, particularly in a muscular athlete.

Surgery for the 'Piriformis Syndrome'

This operation is performed under a general anaesthetic with the patient in the lateral position similar to the approach for a hip joint arthroplasty. An oblique incision is made just distal to a line extending from the posterior superior iliac spine to the tip of the greater trochanter. The incision usually lies within the 'bikini line'. The fibres of the gluteus maximus are split by blunt dissection, although some surgeons prefer to detach this muscle from its insertion to the iliotibial tract to assist exposure.^[70] In our experience, this is unnecessary. The sciatic nerve is initially best found by palpation. It is then carefully exposed from beneath the surrounding fascia and fatty tissue. The PCNT, PN and the IGN should also be identified medial to the sciatic nerve. At this point, any compressive lesion or anatomical variation in the course of the nerve can be visualised and addressed if necessary.^[71] If no abnormality is detected to account for the symptoms, then the piriformis muscle should be divided at its musculo-tendinous junction.^[72] A neurolysis of the nerve is carried out as far distally as the surgical exposure allows.

Decompression of the Sciatic Nerve and PCNT in the Upper Hamstring Region

The surgical approach to this problem has been well described.^[65] An oblique incision is made in the skin, just below the buttock, with the patient in the lateral position. The lower border of the gluteus maximus is identified and the muscle elevated superiorly to expose the region around the ischial tuberosity. Proximal exposure may be further aided by hip flexion. The pathology affecting the nerve can then be visualised. This will be either a fibrous aponeurotic band extending from the biceps femoris origin or local scarring of the upper hamstring

region secondary to trauma or inflammation. The nerve is then fully dissected from the scar tissue or fibrous band and a neurolysis carried out. Care must be taken to avoid inadvertent injury to both of the nerves in this area.

3.11.5 Comment

Given the anatomical relationship of the piriformis to the various nerves in the deep gluteal region, it is possible that the buttock pain represents entrapment of the gluteal nerves and the hamstring pain, entrapment of the PCNT rather than the sciatic nerve alone. This would explain the clinically observed phenomenon in the absence of distal sciatic neurological signs. Whether the piriformis muscle is the cause of the compression has not been clearly established. It is possible that the obturator internus/gemelli complex is an alternative cause of neural compression. For this reason, we suggest that sports medicine clinicians consider using the term 'deep gluteal syndrome' rather than the 'piriformis syndrome'.

4. Investigation of Sport-Related Nerve Entrapment Syndromes

As with all nerve entrapments, the clinical diagnosis is confirmed by electrophysiological studies such as nerve conduction studies and electromyography. These studies assist in the localisation of a nerve lesion, the evaluation of severity and the prognosis of the injury. The details of testing are beyond the scope of this paper and readers are referred the general texts on this subject for further information.^[73,74]

The issue of provocative manoeuvres in conjunction with the standard neurophysiological studies deserves consideration such as described for the sciatic nerve (section 3.11).^[68] In sporting patients, many of the nerve entrapment syndromes may be exercise-related and, hence, asking the patient to exacerbate his or her symptoms prior to the test by performing the exercise that characteristically brings out the symptoms may be critical in establishing a diagnosis. In certain situations, the specific stretch or manoeuvre may need to be re-

peated at the time of electrophysiological testing to assist diagnosis.

The specific neurophysiological diagnostic tests relating to the nerves discussed in this paper are set out in table III.

The role of imaging studies in most focal nerve entrapment syndromes is generally disappointing. Certainly, imaging has a role in detecting the cause of nerve entrapments where trauma, tumours or other space occupying lesions may be secondarily compressing neural structures. If the site of the lesion is proximal, then magnetic resonance scanning is the imaging mode of choice. Unfortunately the resolution of the available imaging modalities is insufficient to image any but the largest nerve trunks.

The diagnostic value of a local anaesthetic nerve block is worth emphasising, particularly where it is necessary to distinguish a specific neuropathy before surgical exploration is contemplated. The adequacy of such a nerve block should be formally assessed by physical examination of the expected motor and/or sensory deficit prior to assessment of the patient's symptoms. Nondiagnostic blocks may reflect poor injection technique rather than an alternative diagnosis. Drawbacks to this approach include the fact that nerve blocks may alleviate pain arising from non-neural structures and that blocks,

Table III. Neurophysiological testing for nerve entrapments

Nerve	Test
Iliohypogastric nerve	Nil
Ilioinguinal nerve	Nerve conduction studies
Genitofemoral nerve	Nil
Obturator nerve	Needle electromyography
Femoral nerve	Nerve conduction studies Needle electromyography
Lateral cutaneous nerve of the thigh	Nerve conduction studies
Sciatic nerve	Nerve conduction studies Needle electromyography Short latency evoked potentials
Pudendal nerve	Needle electromyography
Superior and inferior gluteal nerves	Needle electromyography
Posterior cutaneous nerve of the thigh	Nerve conduction studies

and even nerve resection, proximal to a lesion sometimes do not relieve pain.

5. Treatment of Sport-Related Nerve Entrapment Syndromes

The natural history of most focal entrapment neuropathies, when no specific cause can be identified, is for symptoms to resolve spontaneously within a few weeks or months. If the neuropathy is not very painful, analgesics and other medications used for neuropathic pain should be tried. Therapeutic injections of local anaesthetic and/or corticosteroids may be considered.

Surgical exploration looking for a local compressive lesion should be reserved for those patients who have severe or persistent symptoms, or a clear-cut clinical picture with at least circumstantial evidence of an accessible site of nerve entrapment. If complete traumatic laceration of a nerve is suspected, exploration and primary nerve repair are indicated. In lesser injuries, it is best to wait for spontaneous recovery for several weeks or months before contemplating surgery.

6. Conclusion

Nerve entrapment syndromes around the pelvis are common causes of chronic pain and other neurological symptoms in sport. Many of these syndromes are exercise-related and diagnostic testing must allow for this fact. A knowledge of anatomical possibilities as well as an understanding of the activities and trauma inherent in a given sport will assist the practitioner to diagnose and manage their patient's symptoms appropriately.

References

1. Brukner P, Khan KM. *Clinical Sports Medicine*. Sydney: McGraw-Hill, 1993
2. Baquie P, Brukner P. Injuries presenting to an Australian sports medicine centre. *Clin J Sports Med* 1997; 7: 28-32
3. Kannus P, Aho H, Jarvinen M, et al. Computerised recording of visits to an outpatient sports clinic. *Am J Sports Med* 1987; 15: 79-85
4. Galasko C, Monor T, Lenon G, et al. University of Manchester sports injury clinic. *Br J Sports Med* 1982; 16: 23-6
5. Witman P, Melvin M, Nicholas J. Common problems seen in a metropolitan sports injury clinic. *Phys Sportsmed* 1981; 9: 105-8
6. Fricker P, Taunton J, Ammann W. Osteitis pubis in athletes: infection, inflammation or injury? *Sports Med* 1991; 12 (4): 266-79
7. Bradshaw C, McCrory P, Bell S, et al. Obturator nerve entrapment: a cause of groin pain in athletes. *Am J Sports Med* 1997; 25: 402-8
8. Bradshaw C, McCrory P. Obturator nerve entrapment. *Clin J Sports Med* 1997; 7: 217-9
9. Stewart J. *Focal peripheral neuropathies*. 2nd ed. New York: Raven Press, 1993
10. Missoul C. Nerve Injuries. In: Dee R, editor. *Principles of orthopaedic practice*. New York: McGraw-Hill, 1989
11. Kopell HP, Thompson W. Peripheral nerve entrapments of the lower extremity. *N Engl J Med* 1962; 266: 16-9
12. Mumenthaler M, Schliack H. *Peripheral nerve lesions: diagnosis and therapy*. New York: Thieme, 1991
13. Sunderland S. *Nerves and nerve injuries*. 2nd ed. Edinburgh: Churchill Livingstone, 1978
14. Stulz P, Pfeiffer KM. Peripheral nerve injuries resulting from common surgical procedures in the lower portion of the abdomen. *Arch Surg* 1982; 117: 324-7
15. Kopell H, Thompson W, Postel A. Entrapment neuropathy of the ilioinguinal nerve. *N Engl J Med* 1962; 266: 16-9
16. Knockaert D, D'Heygere FG, Bobbaers H. Ilio-inguinal nerve entrapment: a little known cause of iliac fossa pain. *Postgrad Med J* 1989; 65: 632-5
17. Hahn L. Clinical findings and results of operative treatment in ilio-inguinal nerve entrapment syndrome. *Br J Obstet Gynaecol* 1989; 96: 1080-3
18. Bohm E, Fiorillo A, Pellettieri L. Ilio-inguinal neuralgia: a forgotten disease. *Acta Neurol Scand* 1979; 34: 33-8
19. Smith C, DeLee J, Ramamurthy S. Ilioinguinal neuralgia following iliac bone grafting: report of two cases and review of the literature. *J Bone Joint Surg* 1984; 66A: 1306-8
20. Dawson D, Hallett M, Millender L. *Entrapment Neuropathies*. Boston: Little Brown and Co., 1963
21. Nakano K. The entrapment neuropathies. *Muscle Nerve* 1978; 1: 264-79
22. Starling J, Harms BA, Schroeder M, et al. Diagnosis and treatment of genitofemoral and ilioinguinal entrapment neuralgia. *Surgery* 1987; 102: 581-6
23. Winer JB, Harrison M. Iatrogenic nerve injuries. *Postgrad Med J* 1982; 58: 142-5
24. Komar J. Das Ilioinguinalis Syndrom. *Nervenarzt* 1971; 42: 637-40
25. Lichtenstein I, Schulman A, Amid P, et al. Cause and prevention of postherniorrhaphy neuralgia: a proposed protocol for treatment. *Am J Surg* 1988; 155: 786-90
26. Purves J, Miller J. Inguinal neuralgia: a review of 50 patients. *Can J Surg* 1986; 29: 43-5
27. Sippo W, Gomez A. Nerve entrapment syndromes from lower abdominal surgery. *J Fam Pract* 1987; 25: 585-7
28. Miyazaki F, Shook G. Ilioinguinal nerve entrapment during needle suspension for stress incontinence. *Obstet Gynaecol* 1992; 80: 246-8
29. Starling J, Harms B. Diagnosis and treatment of genitofemoral and ilioinguinal neuralgia. *World J Surg* 1989; 13: 586-91
30. McGee R. Genitofemoral causalgia (a new syndrome). *Can Med Assoc J* 1942; 46: 326-9
31. Lyon E. Genitofemoral causalgia. *Can Med Assoc J* 1945; 53: 213-6
32. Laha R, Rao S, Pidgeon C. Genitofemoral neuralgia. *Surg Neurol* 1977; 8: 280-2
33. O'Brien M. Genito-femoral neuropathy. *BMJ* 1979; 1: 1052

34. Romanes GJ. Cunningham's manual of practical anatomy. Vol. 1. London: Oxford University Press, 1976
35. Clark JM. Obstetrical palsy. *J Bone Joint Surg* 1956; 47B: 806
36. Silski J, Scott R. Obturator nerve palsy resulting from intrapelvic extrusion of cement during total hip arthroplasty. *J Bone Joint Surg* 1985; 67A: 1225-30
37. Weber E, Daube J, Coventry M. Peripheral neuropathies associated with total hip arthroplasty. *J Bone Joint Surg* 1976; 58A: 66-73
38. Sowell A, Ljungdahl I, Spanger L. Thigh neuralgia as a symptom of obturator hernia. *Acta Chir Scand* 1976; 142: 457-9
39. Kozlowski JM, Beck JM. Obturator hernia: an elusive diagnosis. *Arch Surg* 1977; 112: 1001-2
40. Williams P, Trzil K. Management of meralgia paraesthetica. *J Neurosurg* 1991; 74: 76-80
41. Stookey B. Meralgia paraesthetica: etiology and surgical treatment. *JAMA* 1928; 90: 1705-7
42. Stevens H. Meralgia paraesthetica. *Arch Neurol Psychiatr* 1957; 77: 557-74
43. Jefferson D, Eames R. Subclinical entrapment of the lateral femoral cutaneous nerve: an autopsy study. *Muscle Nerve* 1979; 2: 145-54
44. McGregor J, Moncur J. Meralgia paraesthetica: a sport lesion in girl gymnasts. *Br J Sports Med* 1977; 11: 16-7
45. Ecker A, Woltman H. Meralgia paraesthetica: a report of 150 cases. *JAMA* 1938; 110: 1650-2
46. Fulton J. Harvey Cushing: a biography. Springfield (IL): Charles C Thomas, 1946
47. van Eerten F, Polder T, Broere C. Operative treatment of meralgia paraesthetica: transection versus neurolysis. *Neurosurg* 1995; 37: 63-5
48. Nahabedian M, Dellon A. Meralgia paraesthetica: aetiology, diagnosis and outcome of surgical decompression. *Ann Plast Surg* 1995; 25: 590-4
49. Aldrich E, van den Heever C. Suprainguinal ligament approach for the surgical treatment of meralgia paraesthetica. *J Neurosurg* 1989; 70: 492-4
50. Fraser D, Campbell I, Ewing D. Mononeuropathy in diabetes mellitus. *Diabetes* 1979; 28: 96-101
51. Goodman J. Femoral neuropathy in relation to diabetes mellitus. *Diabetes* 1954; 3: 266-73
52. Coppack S, Watkins P. The natural history of diabetic femoral neuropathy. *Q J Med* 1991; 79: 307-13
53. Allen R, Hosker G, Smith A, et al. Pelvic floor damage and childbirth: a neurophysiological study. *Br J Obstet Gynaecol* 1990; 97: 770-9
54. Hofmann A, Jones R, Schoenvogel R. Pudendal nerve neuropathia as a result of traction on the fracture table. *J Bone Joint Surg* 1982; 64A: 136-8
55. Goodson J. Pudendal neuritis from biking [letter]. *N Engl J Med* 1981; 304: 365
56. Desai K, Gingell J. The hazards of long distance cycling. *BMJ* 1989; 298: 1072-3
57. Hinman F. Atlas of uro-surgical anatomy. Philadelphia (PA): WB Saunders & Co., 1993
58. Arnoldussen W, Korten J. Pressure neuropathy of the posterior femoral cutaneous nerve. *Clin Neurol Neurosurg* 1982; 82: 57-60
59. Muller-Vahl H. Isolated complete paralysis of the tensor fasciae latae muscle. *Eur Neurol* 1985; 2: 289-91
60. Rask M. Superior gluteal nerve entrapment syndrome. *Muscle Nerve* 1980; 3: 304-7
61. Pecina M, Krmpotic-Nemanic J, Markiewitz A. Tunnel syndromes: peripheral nerve compression syndromes. 2nd ed. Boca Raton (FL): CRC Press, 1997
62. Pecina M. Contribution to the etiological explanation of the piriformis syndrome. *Acta Anat* 1979; 105: 181-7
63. LaBan M, Meerschaert J, Taylor R. Electromyographic evidence of inferior gluteal nerve compromise; an early representation of recurrent colo-rectal carcinoma. *Arch Phys Med Rehabil* 1982; 63: 33-5
64. Stohr M. Traumatic and postoperative lesions of the lumbosacral plexus. *Arch Neurol* 1978; 35: 757-60
65. Puranen J, Orava S. The hamstring syndrome. A new diagnosis of gluteal sciatic pain. *Am J Sports Med* 1988; 16: 517-21
66. Yeoman W. The relationship of arthritis of the sacro-iliac joint to sciatica. *Lancet* 1928; II: 1119-22
67. Freiburg A, Vinkle T. Sciatica and the sacro-iliac joint. *J Bone Joint Surg* 1934; 16: 126-36
68. Fishman L, Zybert P. Electrophysiologic evidence of piriformis syndrome. *Arch Phys Med Rehabil* 1992; 73: 359-64
69. Synek V. Short latency somatosensory evoked potentials in patients with painful dysaesthesias in peripheral nerve lesions. *Pain* 1987; 29: 49-58
70. Vandertop W, Bosma N. The piriformis syndrome. *J Bone Joint Surg* 1991; 73A: 1095-7
71. Durrani Z, Winnie A. The piriformis muscle syndrome: an under diagnosed cause of sciatica. *J Pain Symptom Manage* 1991; 6: 374-9
72. Solheim L, Siewers P, Paus B. The piriformis muscle syndrome. *Acta Orthop Scand* 1981; 52: 73-5
73. Binnie C, Cooper R, Fowler C, et al. Clinical neurophysiology. Oxford: Butterworth-Heinemann, 1995
74. Kimura J. Electrodiagnosis in diseases of nerve and muscles: principles and practice. 2nd ed. Philadelphia: FA Davis, 1989

Correspondence and reprints: Dr Paul McCrorry, Neurologist and Sports Physician, Olympic Park Sports Medicine Centre, Swan Street, Melbourne 3004, Australia.
E-mail: pmccrorry@compuserve.com