

# 4 Head and Face

## Head Injuries

Paul McCrory<sup>1,2</sup>, Peter D. le Roux<sup>3</sup>, Michael Turner<sup>4</sup>, Ingunn R. Kirkeby<sup>5</sup>, and Karen M. Johnston<sup>6</sup>

<sup>1</sup>University of Melbourne, Melbourne, VIC, Australia

<sup>2</sup>Monash University, Frankston, VIC, Australia

<sup>3</sup>University of Pennsylvania, Philadelphia, PA, USA

<sup>4</sup>British Horseracing Authority, London, UK

<sup>5</sup>Oslo University Hospital, Rikshospitalet, Oslo, Norway

<sup>6</sup>University of Toronto, Toronto, ON, Canada


Clinicians have to recognize and manage a spectrum of head injury ranging from mild concussion through to fatal penetrating brain trauma. The most common form of brain injury is concussion. Sports medicine physicians, trainers, and others involved in athletic care need to have a thorough understanding of the early management of the concussed athlete and the potential sequelae of such injuries that may impact upon the athlete's ability to return to sport. This chapter primarily deals with sport-related head injury.

### Definition

Head trauma is the broad description applied to injuries to the brain or its coverings, skull, soft tissues, and vascular structures of the head and neck. In this chapter, when considering such injuries, the term traumatic brain injury (TBI) will be applied to the injuries of the brain or central nervous system and head injury to incorporate injuries to other structures of the head including the skull and craniofacial bones. Both forms of injury can occur in the same patient. For example, a depressed skull fracture may be associated with a scalp injury, lacerate the dura mater and cause a contusion in the brain.

### Occurrence

TBI is one of the leading causes of morbidity and mortality worldwide. Because of differing injury definitions and methodology, the precise incidence of TBI is

Most common	Less common	Must not be overlooked 
Brain concussion, p. 65	Post-traumatic epilepsy, p. 76 Post-traumatic headache, p. 76	Diffuse cerebral swelling second impact syndrome, p. 71 Cranial fracture, p. 72 Acute subdural hematoma, p. 72 Extradural hematoma, p. 73 Traumatic intracranial hematoma/contusion, p. 74 Traumatic subarachnoid hemorrhage, p. 75

**Table 4.1** Overview of differential diagnoses for acute head injuries. (Reproduced with permission from the Norwegian Sports Medicine Association.)

*The IOC Manual of Sports Injuries, First Edition. Edited by Roald Bahr.  
©2012 International Olympic Committee. Published 2012 by John Wiley & Sons, Ltd.*

problematic. The crude incidence for all traumatic brain injuries is estimated at approximately 300 per 100,000 inhabitants per year with the majority of those suffering a mild TBI. High-risk groups for sport-related TBI include males and those with a previous history of TBI. Males are more than twice as likely to suffer a TBI than females with a peak incidence among the 15–24-year-old population. However, in the nonsporting context, TBI demographics are changing. There now is trifocal age-specific TBI incidence—young children, young adults, and the elderly.

In hospital-based surveys of brain trauma, sporting injuries contribute approximately 10–15% of all cases and the sports most commonly associated with severe brain injuries are golf, equestrian sports and mountain climbing. Sporting-related deaths due to brain injury are fortunately rare, although these injuries have not been rigorously studied outside American and Australian football. The Center for Disease Control now estimates that 1.6–3.8 million sports-related concussions occur each year in the United States.

## Differential Diagnoses

In moderate to severe brain injury, the differential diagnosis is limited and the fact that an athlete has sustained a significant brain injury usually is obvious (see Table 4.1). The critical diagnostic problem in this situation is to sort out the different types of intracranial injury (e.g., subdural hematoma and extradural hematoma) that may present with similar clinical features initially and then determine the most appropriate management priorities.

In mild brain injury and in particular, the subset of concussion, the diagnosis is often missed because the symptoms are subtle, the athlete does not seek medical attention or the athlete recovers rapidly before a full assessment can be made. Most sport-related head injuries occur without loss of consciousness. In this situation, the most common differential diagnosis is that of post-traumatic migraine that may manifest similar early symptoms. The key clinical symptom of concussion used to establish the presence of this injury is cognitive disturbance that may include altered memory, reaction time, or judgment.

## Diagnostic Thinking

The key objectives when assessing any athlete who has sustained a TBI is to:

1. institute an appropriate first aid sideline assessment of the injured athlete;
2. make an accurate diagnosis;
3. manage the injury appropriately, minimizing the risk of any “secondary” injury, such as might be seen with coexistent hypoxia or hypotension;
4. remove safely the athlete from the field of play to an appropriate medical facility for further investigation and assessment;
5. determine subsequently when it is safe for the athlete to return to play.

Although a number of general classification schemes for TBI have been proposed, the most widely used system is the Glasgow Coma Scale (GCS). The GCS is incorporated in the SCAT2 tool (see Figure 4.2, pp. 67). However, the GCS does not provide specific information about the pathophysiologic mechanisms of the injury. The GCS has two distinct and separate uses (a) for serial measurement of brain injury status and (b) to separate TBI into a clinically and prognostically useful injury severity grading. In the former role, an immediate GCS is performed at the time of the initial or baseline assessment of an injured patient and then serially to monitor progress. In the second role, the separation of mild (GCS 13–15),

moderate (GCS 9–12) and severe (GCS  $\leq$ 8) TBI is based upon a scoring system that uses eye opening, verbal response and motor response to standard stimuli and should be measured at 6-hour postinjury after resuscitation has been completed. It is important to note that the term concussion (or commotio cerebri) refers to a different injury construct and is not synonymous with the term “mild TBI,” that is, a concussed athlete may have a normal GCS. The GCS also provides useful information about expected outcome after TBI (see [www.tbi-impact.org/](http://www.tbi-impact.org/) for an online tool to help with predicting prognosis) but not for concussion.

The treating clinician at a sporting event also must decide who should be referred to a hospital emergency facility or neurosurgical center. There are a number of urgent indications that are listed in Table 4.2. While it is acknowledged that a number of these indications are based on anecdotal rather than evidence-based information, these are widely accepted. The overall approach should be “*when in doubt, refer.*” Where no physician is present and the initial management is in the hands of an athletic trainer, physical therapist or paramedic, then an urgent medical referral should be considered mandatory in all cases of head injury.

## Case History

Usually the fact that an athlete has suffered a head injury is obvious to the team medical staff. Head injuries in collision sports are usually the result of direct trauma to the athlete’s head but should also be considered when there has been a rapid acceleration and deceleration type injury but no direct head contact. Eyewitness information or where available, videotape of the episode, is vital to help understand the nature of the injury especially if the athlete is unconscious or incapable of providing a lucid history. Information about the event and about the immediate clinical findings must be directly conveyed to the hospital staff. Key elements of the assessment of a head injured athlete are set out in Table 4.3.

The specific symptoms of acute concussion are outlined in the Pocket SCAT2 tool and the SCAT2 (see Figures 4.1 and 4.2). For practical purposes, the *Pocket SCAT2* can be utilized on-field or on the sideline to screen for concussion and once

Any player who has or develops the following:

- Fractured skull
- Penetrating skull trauma
- Deterioration in conscious state following injury
- Focal neurological signs
- Confusion or impairment of consciousness >30 minutes
- Loss of consciousness >5 minutes
- Persistent vomiting or increasing headache postinjury
- Any convulsive movements
- More than one episode of concussive injury in a session
- Where there is assessment difficulty (e.g., an intoxicated patient)
- Children with head injuries
- High-risk patients (e.g., hemophilia, anticoagulant use)
- Inadequate postinjury supervision
- High-risk injury mechanism (e.g., high-velocity impact)

**Table 4.2** Indications for urgent hospital referral and neuroimaging. (Reproduced with permission from the Norwegian Sports Medicine Association.)

- Time and place of injury
- Mechanism of injury (eyewitness or video)
- Presence or duration of loss of consciousness
- Postinjury symptoms
- Postinjury behavior
- Presence of convulsions postinjury
- Past medical history
- Medication use

**Table 4.3** Early assessment of head injury—history. (Reproduced with permission from the Norwegian Sports Medicine Association.)

concussion diagnosed then the player removed to the medical room and the full SCAT2 assessment tool then used by a physician. If the diagnosis of concussion is confirmed following assessment, then the player should not be returned to play on the day. In addition to postinjury assessment, it is recommended that the SCAT2 be baseline tested in the preseason. This is helpful for interpreting the postconcussion test score as it provides an objective record for possible change.

### Sideline or First-aid Management

It is essential that all team physicians who have an on-field injury management role in their sport have formal training and certification in both first aid and trauma management. Depending upon the country concerned there may be regional differences

HEAD AND FACE

### Pocket SCAT2

Concussion should be suspected in the presence of **any one or more** of the following: symptoms (such as headache), or physical signs (such as unsteadiness), or impaired brain function (e.g. confusion) or abnormal behaviour.

#### 1. Symptoms

Presence of any of the following signs & symptoms may suggest a concussion.

<ul style="list-style-type: none"> <li>▪ Loss of consciousness</li> <li>▪ Seizure or convulsion</li> <li>▪ Amnesia</li> <li>▪ Headache</li> <li>▪ "Pressure in head"</li> <li>▪ Neck Pain</li> <li>▪ Nausea or vomiting</li> <li>▪ Dizziness</li> <li>▪ Blurred vision</li> <li>▪ Balance problems</li> <li>▪ Sensitivity to light</li> <li>▪ Sensitivity to noise</li> </ul>	<ul style="list-style-type: none"> <li>▪ Feeling slowed down</li> <li>▪ Feeling like "in a fog"</li> <li>▪ "Don't feel right"</li> <li>▪ Difficulty concentrating</li> <li>▪ Difficulty remembering</li> <li>▪ Fatigue or low energy</li> <li>▪ Confusion</li> <li>▪ Drowsiness</li> <li>▪ More emotional</li> <li>▪ Irritability</li> <li>▪ Sadness</li> <li>▪ Nervous or anxious</li> </ul>
---	---

#### 2. Memory function

Failure to answer all questions correctly may suggest a concussion.

*"At what venue are we at today?"*  
*"Which half is it now?"*  
*"Who scored last in this game?"*  
*"What team did you play last week / game?"*  
*"Did your team win the last game?"*

---

#### 3. Balance testing

##### Instructions for tandem stance

*"Now stand heel-to-toe with your non-dominant foot in back. Your weight should be evenly distributed across both feet. You should try to maintain stability for 20 seconds with your hands on your hips and your eyes closed. I will be counting the number of times you move out of this position. If you stumble out of this position, open your eyes and return to the start position and continue balancing. I will start timing when you are set and have closed your eyes."*

Observe the athlete for 20 seconds. If they make more than 5 errors (such as lift their hands off their hips; open their eyes; lift their forefoot or heel; step, stumble, or fall; or remain out of the start position for more than 5 seconds) then this may suggest a concussion.

**Any athlete with a suspected concussion should be IMMEDIATELY REMOVED FROM PLAY, urgently assessed medically, should not be left alone and should not drive a motor vehicle.**

**Figure 4.1** Pocket SCAT2 instrument is designed for rapid on-field assessment of concussed athletes.

in certification and accreditation courses; some of the best known include Advanced Trauma Life Support (ATLS); Emergency Management of Severe Trauma (EMST); Pre-Hospital Emergency Care Course (PHECC); Pre-Hospital Trauma Life Support (PHTLS) and the British Association of Immediate Care Course (BASICS). This list is not exhaustive; however, they all deliver the skill set required to appropriately and safely manage acute injuries.

The major priorities at this early stage are the basic principles of first aid. The simple mnemonic DR ABC may be a useful aide-memoire (Table 4.4). When a patient is transferred to an emergency room this same approach in management is taken, that is, ensure a secure airway with proper oxygenation and circulation.

Once these basic aspects of first aid care have been achieved and the patient stabilized, then consideration of removal of the patient from the field to an appropriate facility is necessary. Only trained individuals should remove helmets or neck protective equipment.

At this time, careful assessment for the presence of a cervical spine or other injury is necessary. If an alert patient complains of neck pain, has evidence of neck tenderness or deformity or has neurological signs suggestive of a spinal injury, then neck bracing and transport on a suitable spinal frame is required (see Chapter 5). If the patient is unconscious, then a cervical injury should be assumed until proven otherwise. Airway protection takes precedence over any potential spinal injury.

The clinical management may involve the treatment of a disorientated, confused, unconscious, uncooperative or convulsing patient. The immediate treatment priorities remain the basic first aid principles of ABC—airway, breathing and circulation. Once this has been established and the patient stabilized, a full medical and neurological assessment exam should follow. On site physicians are in an ideal position to initiate the critical early steps in medical care to ensure optimal recovery from a head injury.

## Clinical Examination

When examining a head injured athlete, a structured and focused neurological examination is important. Because the major management priorities at this stage are to establish an accurate diagnosis and exclude a catastrophic intracranial injury, this part of the examination should focus on key clinical findings such as

1. level of consciousness (measured using the GCS);
2. pupil response and conjugate eye movement;
3. motor function.

D	Danger	Ensuring that there are no immediate environmental dangers that may potentially injure the patient or treatment team. This may involve stopping play in a football match or marshalling cars on a motor racetrack.
R	Response	Is the patient conscious? Can he/she talk?
A	Airway	Ensuring a clear and unobstructed airway. Removing any mouthguard or dental device that may be present.
B	Breathing	Ensure the patient is breathing adequately
C	Circulation	Ensure an adequate circulation

**Table 4.4** Initial on-field assessment of concussion. (Reproduced with permission from the Norwegian Sports Medicine Association.)

During the evaluation, one should determine whether the pupils are in the normal position, that is, not deviated to one side and are equal and reactive to light and if all extremities are moving and moving symmetrically in a normal manner. A dilated pupil that does not react to light should be considered an emergency since it may indicate incipient herniation of the brain due to raised intracranial pressure (ICP). In these patients, immediate decompressive surgery may be lifesaving.

A baseline measurement of the Glasgow Coma Score, preferably after initial resuscitation but before additional medications such as sedatives or paralytics are given should be performed in all head-injured patients. The importance of this initial neurologic exam is that it serves as a reference to which other repeated neurologic examinations may be compared and there is little interobserver variability. A GCS of  $\leq 8$  indicates coma and airway intubation and ventilation should be considered urgently. It is necessary to record all clinical findings so that an overall trend in improving or deteriorating mental function can be clearly and objectively documented. In addition, the head and face should be inspected and palpated carefully to look for lacerations, fractures and to check for cerebrospinal fluid (CSF) leak from the nose or ears. Fluid that runs from the nose or ears can be clear or mixed with blood. Bloody CSF when it drips onto a gauze sponge will form a halo. A positive glucose stick test suggests that the fluid is CSF and this can be confirmed in the hospital with B-transferrin analysis. The assessment of cognitive function in this situation is covered on p. 66.

**Vital signs must be recorded following an injury.** Although head injury produces several types of respiratory patterns, an acute rise in ICP with central herniation can lead to an increase in blood pressure and falling pulse rate (the Cushing response). **Hypotension is rarely due to brain injury, except as a terminal event, and alternate sources for the decrease in blood pressure should be aggressively sought and treated.** **This includes major scalp lacerations especially in young children or a cervical spinal cord injury.** Restlessness is a frequent accompaniment of brain injury and can be an early indicator of increased ICP, intracranial bleeding or hypoxia, all of which can aggravate any underlying brain injury. **If the patient is unconscious but restless, attention should be given to the possibility of increasing hypoxia, a distended bladder or painful injuries elsewhere.** Only when these causes have been ruled out, should drug sedation be considered. This point cannot be overstated since hypotension and hypoxia adversely influence outcome following brain injury and are easily treatable factors.

**When time permits, a more thorough physical exam should be performed to exclude coexistent injuries elsewhere in the body,** a sensory evaluation and to detect the late developing signs of skull injury. This includes Battle's sign (subcutaneous hematoma over the mastoid bone) and hemotympanum (blood in the middle ear) that often suggest petrous temporal bone fractures or raccoon eyes (bilateral periorbital hematomas) that are common with other skull base fractures. Injury to cranial nerves, for example, the 7th (facial) and 8th (vestibulocochlear) nerve, is common after skull base fractures.

In recent times, the application of simple neuropsychological tests has created considerable interest as a means to objectively assess the mental status of concussed athletes. The standard approach of asking the orientation items (e.g., day, date, year, time, and date of birth) has been shown to be unreliable in following concussive brain injury. More useful are questions of recent or working memory. These are included in the Maddock's questions (Table 4.5) and in the Pocket SCAT2 (Figure 4.1) and SCAT2 (Figure 4.2).

- Which ground are we at?
- Which team are we playing today?
- Who is your opponent at present?
- Which quarter is it?
- How far into the quarter is it?
- Which side scored the last goal?
- Which team did we play last week?
- Did we win last week?

**Table 4.5** Postconcussion memory assessment (Maddock's questions). (Reproduced with permission from the Norwegian Sports Medicine Association.)

Having determined the presence of a concussive injury, the patient needs to be serially monitored until full recovery ensues. If the concussed player is discharged home after recovery, then he should be in the care of a responsible adult. Each patient and his attendant must be given a head injury advice card upon discharge. An example of a head injury card is included in the SCAT2 (Figure 4.2, p. 67).

## Supplemental Examinations

**Computerized tomography (CT).** A brain CT scan is the most useful diagnostic test after head injury. CT evaluation should proceed as soon as the patient is hemodynamically stable and all immediately life-threatening injuries have been addressed. Even if a first CT scan is normal, repeat imaging should be considered when there is patient deterioration since delayed hematomas, evolution of a small contusion or cerebral edema may evolve over time. There may be practical difficulties especially in children when attempting to perform a CT scan and often children, especially if young, may need to be sedated or anaesthetized to achieve an optimum scan.

Indications for emergent cranial CT imaging in the initial evaluation of the head-injured patient are similar to the points already outlined in Table 4.2. The primary goal of imaging is to establish whether there is a surgical lesion, that is, intracranial hemorrhage. A depressed level of consciousness and in particular a GCS  $\leq 8$ , are the strongest predictors of intracranial hemorrhage. Other signs that suggest surgical pathology include focal motor weakness and an asymmetrical pupil exam. There may be situations however where the clinical examination is obscured by alcohol, drugs, metabolic derangement or postictal state or where the ability to access the patient for serial neurologic examinations is problematic. In such cases, early CT scanning is recommended to enable accurate decision-making. An important question is who needs a head CT scan when their level of consciousness is normal (i.e., GCS is 15)? Guidelines such as the Canadian Head CT Rules and the New Orleans Criteria suggest that factors such as age >60 years, headache, vomiting, intoxication, retrograde amnesia, confusion, loss of consciousness, seizures, visible trauma above the clavicles and injury mechanism indicate a need for a head CT. Acute blood is hyperdense on a noncontrast head CT scan. The head CT also is examined for "mass effect," for example, the amount of midline shift of the third ventricle and the condition of the perimesencephalic cisterns. These can help guide surgical decision-making.

However, a normal head CT scan does not always exclude a TBI or the need for neurosurgical consultation. About 20% of patients admitted to hospital after even mild TBI may develop posttraumatic abnormalities on subsequent imaging even after the initial head CT scan was normal.

**Magnetic resonance imaging (MRI).** The role of MRI in the evaluation of acute head trauma is limited, in part because it is time-consuming, expensive, and less sensitive to acute hemorrhage than CT. In addition, access to critically ill or unconscious patients is restricted during the time of image acquisition that is much longer than CT, and the strong magnetic fields generated by the scanner necessitate the use of nonferromagnetic resuscitative equipment. However, MRI can be useful in the subacute or chronic phases after injury to help explain failure to improve in the days following injury. Advanced MRI, for example, functional MRI, Diffusion Tensor Imaging or spectroscopy, can be useful in research studies or assessment of long term recovery.

**Skull X-ray examination.** Skull X-ray series (AP, Caldwell, Waters, and lateral views) have been replaced by the use of CT scans and are very rarely obtained. However, plain skull radiographs are inexpensive and can easily be obtained in an emergency room and if a fracture is present particularly when there is a focal finding or depressed level of consciousness, suggest an extradural hemorrhage. The overall predictive value of skull X-rays is low.

**Neck imaging.** Cervical spine injury is common in patients with head injury. Consequently plain cervical X-rays, CT and even MRI are indicated where appropriate.

**Vascular imaging.** Blood vessels in the neck and head can be examined using several tests including Doppler ultrasound, CT angiography, MR angiography or venography and, if necessary, digital subtraction angiography. Vascular studies should be considered when there is penetrating injury, a neurologic deficit that is not explained by head CT scan, fractures over the venous sinus, some neck injuries, for example, fractures through the foramen transversarium or certain craniofacial injuries such as Lefort II or III fractures. Early identification of vascular injuries can help reduce the incidence of stroke.

**Neuropsychological testing.** Neuropsychological testing to determine recovery from TBI is accepted worldwide. In recent decades, sports such as Australian football, American professional football and ice hockey (NHL) have followed similar strategies. More detail is included in the section Rehabilitation of Acute Head and Facial Injuries on p. 96.

## Specific Diagnoses—Common Injuries

### Brain Concussion—*Commotio Cerebri*

Concussion is defined as a complex pathophysiological process affecting the brain, induced by traumatic biomechanical forces, either by a direct blow to the head, face, neck or elsewhere on the body with an “impulsive” force transmitted to the head. Research suggests that linear acceleration or rotational shearing forces may result in short-lived neurochemical, metabolic or gene-expression changes. Concussion typically results in the rapid onset of short-lived impairment of neurologic function that resolves spontaneously. Although concussion may result in neuropathological changes, the acute clinical symptoms largely reflect a functional disturbance rather than a structural injury, although the athlete may have sustained a significant impact to the brain. Per definition, no abnormality is seen on standard structural neuroimaging studies. Concussion results in a graded set of clinical symptoms that may or may not involve loss of consciousness. Resolution of the clinical and cognitive symptoms typically follows a sequential course; however, it is important to note that in a small percentage of cases postconcussive symptoms may be prolonged.



Frequently, in episodes of mild concussion (“bell ringers”), the athlete will be dazed or stunned for a period of seconds only and continue playing. Alert medical and training staff should closely observe the actions of a player who has received a knock to the head for any signs of impaired performance.

- **Symptoms and signs:** Common symptoms of concussion include headache, nausea, dizziness and balance problems, blurred vision, memory loss, a feeling of slowness or fatigue. A more complete list of symptoms is shown in Figure 4.2 (p. 67). These symptoms are not specific to concussion and in some cases may present in a delayed fashion. Clinical features that are more specific to a diagnosis of concussion include: loss of consciousness/impaired conscious state, concussive convulsions/impact seizures, confusion or attention deficit, memory disturbance (unaware of period, opposition, game score) and balance disturbance. These features however may not be present in all cases and in some cases may present in a delayed fashion. Other physical signs with concussion include poor coordination, slow to answer questions or follow directions, easily distracted, poor concentration, displaying unusual or inappropriate emotions, vomiting, vacant stare/glassy eyed, personality changes, slurred speech, double/blurred vision.
- **Diagnosis:** The Pocket SCAT2 (Figure 4.1) can be utilized on the sideline to screen for concussion and once concussion is diagnosed then the player can be removed to the medical room. The full SCAT2 assessment tool (Figure 4.2) is then used by a physician. The diagnosis is made by having any new concussion symptoms or by failing either of the cognition or balance components of the Pocket SCAT2. The full SCAT2 is a more detailed medical assessment form that also incorporates additional cognitive questions and physical examination findings. This tool also incorporates the Maddock’s questions and the SAC. Any abnormality on any component of this test would indicate a concussive injury. Generally, an uncomplicated concussion does not need routine neuroimaging. However, imaging has a role in the exclusion of suspected intracranial injury (Table 4.2). There is no reliable or scientifically validated system of grading the severity of sports-related concussion. At the present time, there are at least 45 published anecdotal severity scales. The danger is that athletes and/or their coaches may “shop around” for a scale that is not in their best medical interests. At the end of the day, good clinical judgment should prevail over published anecdotal grading scales.
- **Treatment:** Once concussion is diagnosed, then the player should be removed from the game or training and not return to play on that day. A variety of immediate motor phenomena (e.g., tonic posturing) or convulsive movements may accompany a concussion. Although dramatic, these are a nonepileptic manifestation of concussion, are generally benign and require no specific management beyond the standard treatment of the underlying concussive injury. The principal concern of premature return to play of a concussed athlete is that due to the impaired cognitive function (e.g., slowed information processing, reduced attention) the athlete will sustain further injury (both concussive and other) when returning to a dangerous playing environment. Furthermore, if a player recommences playing while symptomatic, postconcussive symptoms may be prolonged. This may also increase the chance of developing the “postconcussive syndrome,” in which fatigue, difficulty in concentration and headaches persist for some time, often months, following the original injury. This syndrome is uncommon in sport. These patients should undergo formal neuropsychological testing as well as an MRI brain scan. If these tests are normal, there is no specific treatment other than rest and reassurance. Following a concussive injury, players should be returned to play in a graduated fashion once clinical features have resolved and cognitive function returned to “baseline.” When considering return to play, the athlete should be off all medications at the time of considering commencement of the rehabilitation phase or at



Name \_\_\_\_\_

Sport/team \_\_\_\_\_

Date/time of injury \_\_\_\_\_

Date/time of assessment \_\_\_\_\_

Age \_\_\_\_\_ Gender  M  F

Years of education completed \_\_\_\_\_

Examiner \_\_\_\_\_

**What is the SCAT2?**

This tool represents a standardized method of evaluating injured athletes for concussion and can be used in athletes aged from 10 years and older. It supersedes the original SCAT published in 2005<sup>2</sup>. This tool also enables the calculation of the Standardized Assessment of Concussion (SAC)<sup>3,4</sup> score and the Maddocks questions<sup>5</sup> for sideline concussion assessment.

**Instructions for using the SCAT2**

The SCAT2 is designed for the use of medical and health professionals. Preseason baseline testing with the SCAT2 can be helpful for interpreting post-injury test scores. Words in *italics* throughout the SCAT2 are the instructions given to the athlete by the tester.

This tool may be freely copied for distribution to individuals, teams, groups and organizations.

**What is a concussion?**

A concussion is a disturbance in brain function caused by a direct or indirect force to the head. It results in a variety of non-specific symptoms (like those listed below) and often does not involve loss of consciousness. Concussion should be suspected in the presence of **any one or more** of the following:

- Symptoms (such as headache), or
- Physical signs (such as unsteadiness), or
- Impaired brain function (e.g. confusion) or
- Abnormal behaviour.

**Any athlete with a suspected concussion should be REMOVED FROM PLAY, medically assessed, monitored for deterioration (i.e., should not be left alone) and should not drive a motor vehicle.**

**Symptom Evaluation**

**How do you feel?**

You should score yourself on the following symptoms, based on how you feel now.

	none	mild	moderate	severe			
Headache	0	1	2	3	4	5	6
"Pressure in head"	0	1	2	3	4	5	6
Neck Pain	0	1	2	3	4	5	6
Nausea or vomiting	0	1	2	3	4	5	6
Dizziness	0	1	2	3	4	5	6
Blurred vision	0	1	2	3	4	5	6
Balance problems	0	1	2	3	4	5	6
Sensitivity to light	0	1	2	3	4	5	6
Sensitivity to noise	0	1	2	3	4	5	6
Feeling slowed down	0	1	2	3	4	5	6
Feeling like "in a fog"	0	1	2	3	4	5	6
"Don't feel right"	0	1	2	3	4	5	6
Difficulty concentrating	0	1	2	3	4	5	6
Difficulty remembering	0	1	2	3	4	5	6
Fatigue or low energy	0	1	2	3	4	5	6
Confusion	0	1	2	3	4	5	6
Drowsiness	0	1	2	3	4	5	6
Trouble falling asleep (if applicable)	0	1	2	3	4	5	6
More emotional	0	1	2	3	4	5	6
Irritability	0	1	2	3	4	5	6
Sadness	0	1	2	3	4	5	6
Nervous or Anxious	0	1	2	3	4	5	6

**Total number of symptoms** (Maximum possible 22)

**Symptom severity score**

(Add all scores in table, maximum possible: 22 x 6 = 132)

Do the symptoms get worse with physical activity?  Y  N

Do the symptoms get worse with mental activity?  Y  N

**Overall rating**

If you know the athlete well prior to the injury, how different is the athlete acting compared to his / her usual self? Please circle one response.

no different  very different  unsure

Figure 4.2 SCAT2 instrument is designed for full medical assessment of concussed athletes.

## Cognitive & Physical Evaluation

**1 Symptom score** (from page 1)  
 22 minus number of symptoms of 22

**2 Physical signs score**  
 Was there loss of consciousness or unresponsiveness?  Y  N  
 If yes, how long? \_\_\_\_\_ minutes  
 Was there a balance problem/unsteadiness?  Y  N  
**Physical signs score** (1 point for each negative response) of 2

**3 Glasgow coma scale (GCS)**

**Best eye response (E)**

No eye opening	1
Eye opening in response to pain	2
Eye opening to speech	3
Eyes opening spontaneously	4

**Best verbal response (V)**

No verbal response	1
Incomprehensible sounds	2
Inappropriate words	3
Confused	4
Oriented	5

**Best motor response (M)**

No motor response	1
Extension to pain	2
Abnormal flexion to pain	3
Flexion/Withdrawal to pain	4
Localizes to pain	5
Obeys commands	6

**Glasgow Coma score (E + V + M)** of 15  
 GCS should be recorded for all athletes in case of subsequent deterioration.

**4 Sideline Assessment – Maddocks Score**  
*"I am going to ask you a few questions, please listen carefully and give your best effort."*

**Modified Maddocks questions** (1 point for each correct answer)

At what venue are we at today?	0	1
Which half is it now?	0	1
Who scored last in this match?	0	1
What team did you play last week/game?	0	1
Did your team win the last game?	0	1

**Maddocks score** of 5  
 Maddocks score is validated for sideline diagnosis of concussion only and is not included in SCAT 2 summary score for serial testing.

**5 Cognitive assessment**  
**Standardized Assessment of Concussion (SAC)**

**Orientation** (1 point for each correct answer)

What month is it?	0	1
What is the date today?	0	1
What is the day of the week?	0	1
What year is it?	0	1
What time is it right now? (within 1 hour)	0	1

**Orientation score** of 5

**Immediate memory**  
*"I am going to test your memory. I will read you a list of words and when I am done, repeat back as many words as you can remember, in any order."*

**Trials 2 & 3:**  
*"I am going to repeat the same list again. Repeat back as many words as you can remember in any order, even if you said the word before."*

Complete all 3 trials regardless of score on trial 1 & 2. Read the words at a rate of one per second. Score 1 pt. for each correct response. Total score equals sum across all 3 trials. Do not inform the athlete that delayed recall will be tested.

List	Trial 1	Trial 2	Trial 3	Alternative word list					
elbow	0	1	0	1	0	1	candle	baby	finger
apple	0	1	0	1	0	1	paper	monkey	penny
carpet	0	1	0	1	0	1	sugar	perfume	blanket
saddle	0	1	0	1	0	1	sandwich	sunset	lemon
bubble	0	1	0	1	0	1	wagon	iron	insect
<b>Total</b>									

**Immediate memory score** of 15

**Concentration**  
**Digits Backward:**  
*"I am going to read you a string of numbers and when I am done, you repeat them back to me backwards, in reverse order of how I read them to you. For example, if I say 7-1-9, you would say 9-1-7."*  
 If correct, go to next string length. If incorrect, read trial 2. One point possible for each string length. Stop after incorrect on both trials. The digits should be read at the rate of one per second.

	0	1	Alternative digit lists
4-9-3	0	1	6-2-9 5-2-6 4-1-5
3-8-1-4	0	1	3-2-7-9 1-7-9-5 4-9-6-8
6-2-9-7-1	0	1	1-5-2-8-6 3-8-5-2-7 6-1-8-4-3
7-1-8-4-6-2	0	1	5-3-9-1-4-8 8-3-1-9-6-4 7-2-4-8-5-6

**Months in Reverse Order:**  
*"Now tell me the months of the year in reverse order. Start with the last month and go backward. So you'll say December, November ... Go ahead"*

1 pt. for entire sequence correct  
 Dec-Nov-Oct-Sept-Aug-Jul-Jun-May-Apr-Mar-Feb-Jan 0 1

**Concentration score** of 5

<sup>1</sup> This tool has been developed by a group of international experts at the 3<sup>rd</sup> International Consensus meeting on Concussion in Sport held in Zurich, Switzerland in November 2008. The full details of the conference outcomes and the authors of the tool are published in British Journal of Sports Medicine, 2009, volume 43, supplement 1. The outcome paper will also be simultaneously co-published in the May 2009 issues of Clinical Journal of Sports Medicine, Physical Medicine & Rehabilitation, Journal of Athletic Training, Journal of Clinical Neuroscience, Journal of Science & Medicine in Sport, Neurosurgery, Scandinavian Journal of Science & Medicine in Sport and the Journal of Clinical Sports Medicine.

<sup>2</sup> McCrory P et al. Summary and agreement statement of the 2<sup>nd</sup> International Conference on Concussion in Sport, Prague 2004. British Journal of Sports Medicine. 2005; 39: 196-204

<sup>3</sup> McCrea M. Standardized mental status testing of acute concussion. Clinical Journal of Sports Medicine. 2001; 11: 176-181

<sup>4</sup> McCrea M, Randolph C, Kelly J. Standardized Assessment of Concussion: Manual for administration, scoring and interpretation. Waukesha, Wisconsin, USA.

<sup>5</sup> Maddocks, DL; Dicker, GD; Saling, MM. The assessment of orientation following concussion in athletes. Clin J Sport Med. 1995;5(1):32-3

<sup>6</sup> Guskiewicz KM. Assessment of postural stability following sport-related concussion. Current Sports Medicine Reports. 2003; 2: 24-30

Figure 4.2 Continued

**6 Balance examination**

This balance testing is based on a modified version of the Balance Error Scoring System (BESS)<sup>6</sup>. A stopwatch or watch with a second hand is required for this testing.

**Balance testing**  
*"I am now going to test your balance. Please take your shoes off, roll up your pant legs above ankle (if applicable), and remove any ankle taping (if applicable). This test will consist of three twenty second tests with different stances."*

(a) **Double leg stance:**  
*"The first stance is standing with your feet together with your hands on your hips and with your eyes closed. You should try to maintain stability in that position for 20 seconds. I will be counting the number of times you move out of this position. I will start timing when you are set and have closed your eyes."*

(b) **Single leg stance:**  
*"If you were to kick a ball, which foot would you use? [This will be the dominant foot] Now stand on your non-dominant foot. The dominant leg should be held in approximately 30 degrees of hip flexion and 45 degrees of knee flexion. Again, you should try to maintain stability for 20 seconds with your hands on your hips and your eyes closed. I will be counting the number of times you move out of this position. If you stumble out of this position, open your eyes and return to the start position and continue balancing. I will start timing when you are set and have closed your eyes."*

(c) **Tandem stance:**  
*"Now stand heel-to-toe with your non-dominant foot in back. Your weight should be evenly distributed across both feet. Again, you should try to maintain stability for 20 seconds with your hands on your hips and your eyes closed. I will be counting the number of times you move out of this position. If you stumble out of this position, open your eyes and return to the start position and continue balancing. I will start timing when you are set and have closed your eyes."*

**Balance testing – types of errors**

1. Hands lifted off iliac crest
2. Opening eyes
3. Step, stumble, or fall
4. Moving hip into > 30 degrees abduction
5. Lifting forefoot or heel
6. Remaining out of test position > 5 sec

Each of the 20-second trials is scored by counting the errors, or deviations from the proper stance, accumulated by the athlete. The examiner will begin counting errors only after the individual has assumed the proper start position. **The modified BESS is calculated by adding one error point for each error during the three 20-second tests. The maximum total number of errors for any single condition is 10.** If a athlete commits multiple errors simultaneously, only one error is recorded but the athlete should quickly return to the testing position, and counting should resume once subject is set. Subjects that are unable to maintain the testing procedure for a minimum of **five seconds** at the start are assigned the highest possible score, ten, for that testing condition.

Which foot was tested:  Left  Right  
 (i.e. which is the **non-dominant** foot)

Condition	Total errors
Double Leg Stance (feet together)	of 10
Single leg stance (non-dominant foot)	of 10
Tandem stance (non-dominant foot at back)	of 10
<b>Balance examination score (30 minus total errors)</b>	<b>of 30</b>

**7 Coordination examination**

**Upper limb coordination**  
 Finger-to-nose (FTN) task: *"I am going to test your coordination now. Please sit comfortably on the chair with your eyes open and your arm (either right or left) outstretched (shoulder flexed to 90 degrees and elbow and fingers extended). When I give a start signal, I would like you to perform five successive finger to nose repetitions using your index finger to touch the tip of the nose as quickly and as accurately as possible."*

Which arm was tested:  Left  Right

Scoring: 5 correct repetitions in < 4 seconds = 1

Note for testers: Athletes fail the test if they do not touch their nose, do not fully extend their elbow or do not perform five repetitions. Failure should be scored as 0.

**Coordination score** of 1

**8 Cognitive assessment**

**Standardized Assessment of Concussion (SAC)**

**Delayed recall**  
*"Do you remember that list of words I read a few times earlier? Tell me as many words from the list as you can remember in any order."*

Circle each word correctly recalled. Total score equals number of words recalled.

List	Alternative word list		
elbow	candle	baby	finger
apple	paper	monkey	penny
carpet	sugar	perfume	blanket
saddle	sandwich	sunset	lemon
bubble	wagon	iron	insect

**Delayed recall score** of 5

**Overall score**

Test domain	Score
Symptom score	of 22
Physical signs score	of 2
Glasgow Coma score (E + V + M)	of 15
Balance examination score	of 30
Coordination score	of 1
<b>Subtotal</b>	<b>of 70</b>
Orientation score	of 5
Immediate memory score	of 15
Concentration score	of 5
Delayed recall score	of 5
<b>SAC subtotal</b>	<b>of 30</b>
<b>SCAT2 total</b>	<b>of 100</b>
<b>Maddocks Score</b>	<b>of 5</b>

Definitive normative data for a SCAT2 "cut-off" score is not available at this time and will be developed in prospective studies. Embedded within the SCAT2 is the SAC score that can be utilized separately in concussion management. The scoring system also takes on particular clinical significance during serial assessment where it can be used to document either a decline or an improvement in neurological functioning.

**Scoring data from the SCAT2 or SAC should not be used as a stand alone method to diagnose concussion, measure recovery or make decisions about an athlete's readiness to return to competition after concussion.**

Figure 4.2 Continued

## Athlete Information

Any athlete suspected of having a concussion should be removed from play, and then seek medical evaluation.

### Signs to watch for

Problems could arise over the first 24-48 hours. You should not be left alone and must go to a hospital at once if you:

- Have a headache that gets worse
- Are very drowsy or can't be awakened (woken up)
- Can't recognize people or places
- Have repeated vomiting
- Behave unusually or seem confused; are very irritable
- Have seizures (arms and legs jerk uncontrollably)
- Have weak or numb arms or legs
- Are unsteady on your feet; have slurred speech

Remember, it is better to be safe.

Consult your doctor after a suspected concussion.

### Return to play

Athletes should not be returned to play the same day of injury. When returning athletes to play, they should follow a stepwise symptom-limited program, with stages of progression. For example:

1. rest until asymptomatic (physical and mental rest)
2. light aerobic exercise (e.g. stationary cycle)
3. sport-specific exercise
4. non-contact training drills (start light resistance training)
5. full contact training after medical clearance
6. return to competition (game play)

There should be approximately 24 hours (or longer) for each stage and the athlete should drop back to the previous asymptomatic level if any post-concussive symptoms recur. Resistance training should only be added in the later stages.

Medical clearance should be given before return to play.

Tool	Test domain	Time	Score			
		Date tested				
		Days post injury				
SCAT2	Symptom score					
	Physical signs score					
	Glasgow Coma score (E + V + M)					
	Balance examination score					
	Coordination score					
SAC	Orientation score					
	Immediate memory score					
	Concentration score					
	Delayed recall score					
<b>SAC Score</b>						
<b>Total</b>	<b>SCAT2</b>					
<b>Symptom severity score (max possible 132)</b>						
<b>Return to play</b>			<input type="checkbox"/> Y <input type="checkbox"/> N	<input type="checkbox"/> Y <input type="checkbox"/> N	<input type="checkbox"/> Y <input type="checkbox"/> N	<input type="checkbox"/> Y <input type="checkbox"/> N

### Additional comments

## Concussion injury advice (To be given to concussed athlete)

This patient has received an injury to the head. A careful medical examination has been carried out and no sign of any serious complications has been found. It is expected that recovery will be rapid, but the patient will need monitoring for a further period by a responsible adult. Your treating physician will provide guidance as to this timeframe.

**If you notice any change in behaviour, vomiting, dizziness, worsening headache, double vision or excessive drowsiness, please telephone the clinic or the nearest hospital emergency department immediately.**

#### Other important points:

- Rest and avoid strenuous activity for at least 24 hours
- No alcohol
- No sleeping tablets
- Use paracetamol or codeine for headache. Do not use aspirin or anti-inflammatory medication
- Do not drive until medically cleared
- Do not train or play sport until medically cleared

Clinic phone number

Patient's name

Date/time of injury

Date/time of medical review

Treating physician

Contact details or stamp

Figure 4.2 Continued

the final medical assessment. Return to sport is not advisable while symptoms are present as exercise appears to prolong the condition. More detail of the rehabilitation process and return to sport following concussion are included in the section Rehabilitation of Acute Head and Facial Injuries on pp. 96–97.

- **Prognosis:** Most sports-related concussive injuries are uncomplicated and recover fully over 1–3 weeks. However, it is worth noting that detailed neuropsychological testing shows that 20% of athletes will still have unrecognized cognitive deficits 10 days after concussion. For this reason, reliance on nonscientific nostrums (“miss a week”) or symptoms alone to guide return to play is not recommended as best practice care. This fact highlights the important role of neuropsychological testing to inform clinical decision-making and as one of the cornerstones of management. In postconcussive athletes with persistent symptoms or cognitive deficits (>14 days) consideration of referral to a multidisciplinary concussion program may be worthwhile. One of the key problems to consider in this setting is mental health issues (such as depression, anxiety and suicide) that have been reported as consequence of TBI including sports concussion. Neuroimaging studies using functional MRI suggest that a chronic symptoms and depressed mood following concussion may reflect an underlying pathophysiological abnormality consistent with a limbic-frontal model of depression. All players with ongoing symptoms or a prolonged clinical course should be screened for depression using standard clinical tools, for example, Hospital Anxiety and Depression Scale, Beck Depression Inventory.

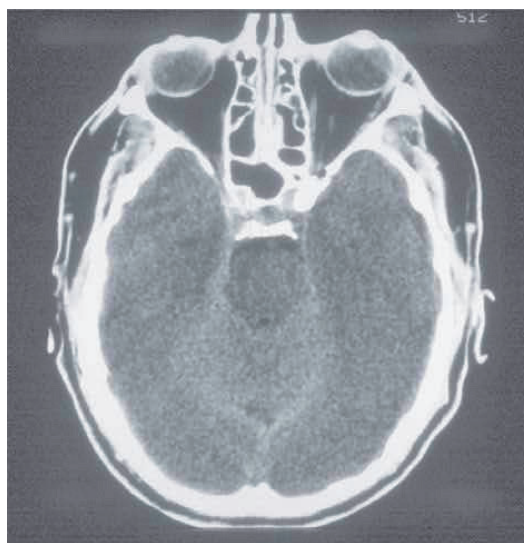## Other Specific Diagnoses

### Diffuse Cerebral Swelling and Second Impact Syndrome !

Second impact syndrome is frequently mentioned in the concussion literature but, surprisingly, has little scientific evidence for its existence. It is a term used to describe the potential catastrophic consequences resulting from a second concussive blow to the head before an individual has fully recovered from the symptoms of a previous concussion. The second head injury is believed to result in loss of cerebrovascular auto-regulation, which in turn leads to brain swelling secondary to increased cerebral blood flow (Figure 4.3). There is a lack of evidence to support the claim that the second impact is a risk factor for diffuse cerebral swelling. However, there is evidence that acute (and delayed) brain swelling may occur following a single blow to the head, in association with a structural injury such as a subdural hematoma and also in disorders of calcium channels, suggesting a possible genetic basis for some of these cases. Such events are virtually only seen in children and adolescents.

- **Symptoms and signs:** Anecdotal reports usually record an athlete collapsing on a sporting field or after practice. A blow to the head may be witnessed but typically is not. The clinical features are those of an unconscious athlete.
- **Diagnosis:** Diagnosis is usually made with a urgent CT brain scan or MRI. Clinical examination, for example, papilledema on fundoscopy, decerebrate posturing, may also provide a clue to the diagnosis.
- **Treatment:** If cerebral swelling is suspected or noted on imaging studies an urgent neurosurgical consultation is required. Elevated ICP requires a variety of

**Figure 4.3** Axial CT images of the brain that demonstrate diffuse cerebral swelling with sulcus effacement and loss of ventricular and cisternal spaces. (Reproduced with permission from the Norwegian Sports Medicine Association.)



treatments. Adequate analgesia, sedation, correction of physiologic derangements and mild head elevation (15° to 30°) are the initial treatments when elevated ICP is suspected. Specific treatments that should be guided by an ICP monitor include: sedation and mechanical ventilation, hyperventilation in select patients, ventricular CSF drainage, osmotherapy (e.g., mannitol or hypertonic saline), blood pressure control, induced coma or surgery when indicated.

- **Prognosis:** Mortality in this condition approaches 100%.

### Cranial Fracture—Skull Fracture !

All types of athletic activity in which trauma to the head occurs have the potential to cause a cranial fracture. Cranial fractures can be divided into three broad categories: linear fractures, skull base fractures and depressed fractures. Skull fractures can be further classified as open (associated with an overlying scalp laceration) or closed and as simple or comminuted. Most linear fractures are uncomplicated and occur over the lateral convexities of the skull. However the presence of a linear fracture in the temporal region often can be associated with an acute extradural hematoma. Fractures that involve air sinuses or overlie venous sinuses in the skull require special consideration. A depressed fracture caused by a blow to the head from even a relatively small object may cause the bone fragments to impact or tear the dura mater or the brain. These fractures can be associated with brain contusions, CSF leaks and seizures. Basal skull fractures involve the floor of the anterior and middle cranial fossas. These fractures may be associated with cranial nerve and vascular injuries.

- **Symptoms and signs:** Athletes with a cranial fracture usually have a headache and may or may not have symptoms of an underlying brain injury. Local soft tissue swelling may also indicate an underlying fracture. The scalp should be carefully inspected and palpated to establish whether the skull fracture is open or closed. A Battle's sign or raccoon eyes suggest a basal skull fracture. Rhinorrhea and otorrhea indicate that skull fracture is associated with torn dural membranes.
- **Diagnosis:** The diagnosis is usually made with a plain skull X-ray or CT scan of the brain.
- **Management:** In all cases of skull fracture, especially if a CSF leak is present, an urgent neurosurgical consultation is required. When a skull fracture is suspected, the patient should always be hospitalized for observation and neurosurgical evaluation. The physician should cover the injured area of an open cranial fracture with a sterile dressing. Fractures that are depressed beyond the thickness of the inner cranial table often require surgical treatment as do fractures that involve the posterior table of the frontal sinus particularly when there is pneumocephalus. CSF leaks usually will respond to bed rest and head elevation but some may require CSF drainage through a lumbar or ventricular drain and rarely direct repair. Prophylactic antibiotic treatment is not recommended for CSF leaks.
- **Prognosis:** Linear fractures heal in a few months to a year, and if no additional injury occurs, the athlete can often return to her sport. The grade of brain injury will usually determine the outcome. The prognosis is often good when the brain and membranes are uninjured. Patients who require a craniotomy to repair a frontal sinus fracture or depressed skull fracture may not be able to participate further in collision or contact sports.

### Acute Subdural Hematoma !

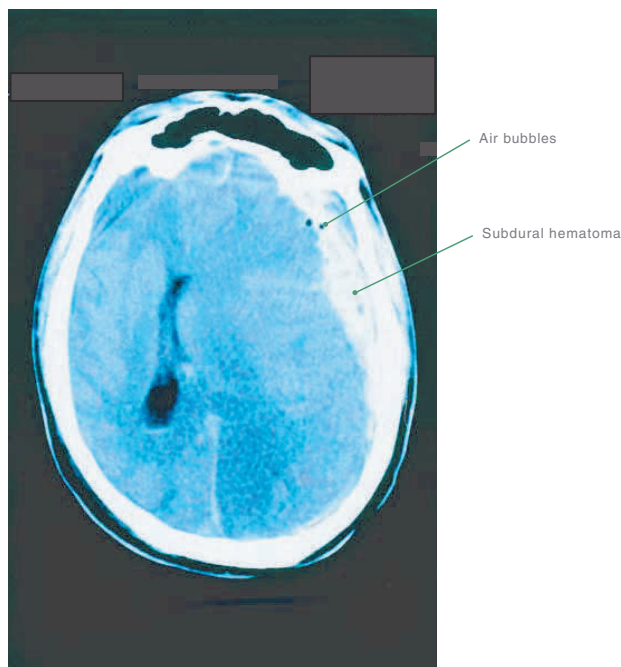
Subdural hematomas (Figure 4.4) may result from either nonpenetrating or penetrating trauma to the head but typically are associated with rapid acceleration and deceleration that tear small bridging veins between the brain and dura. Extravasation

of blood into the subdural space causes hematoma formation. In addition, subdural hematomas frequently are associated with underlying brain injury, for example, contusions. These injuries are typically seen following falls on hard surfaces or assaults with nondeformable objects rather than low velocity injuries. They are also more common in elderly subjects and should be considered into those taking medications such as anticoagulants. Acute subdural hematomas are the most common traumatic mass lesions and occur in 30% of severely head-injured patients. Chronic subdural hematomas may occur in individuals with brain atrophy and evolve over several weeks even after very mild head injury.

- **Symptoms and signs:** Clinical signs and symptoms depend on the size and location of the subdural hematoma and how quickly it developed. In general, the more severe the head injury the more likely the presence of an acute subdural hematoma. There may be a brief period of confusion or loss of consciousness but many patients are in coma from the onset. Few patients remain lucid throughout their course. Impaired alertness and cognitive function are found frequently on initial examination. Soft tissue injuries may be seen at the site of impact but their absence does not mean there is no intracranial injury. Enlargement of the hematoma or an increase in edema surrounding the hematoma produces additional mass effect, with further depression of the patient's level of consciousness, increases in motor or speech deficit, and eventually ipsilateral compression of the third nerve and midbrain (i.e., herniation).
- **Diagnosis:** In the acute phase, the diagnosis is usually made with a CT scan of the brain.
- **Treatment:** A patient with a subdural hematoma requires urgent neurosurgical consultation. Initial management depends on the clinical condition but is aimed at controlling ICP (see the preceding text). In a patient with a depressed level of consciousness, focal findings or elevated ICP surgical evacuation through a craniotomy is necessary. In addition, subdural hematomas that on CT are thicker than 1 cm and associated with >5 mm of midline shift should be removed. Operative treatment is directed toward evacuation of the entire subdural hematoma; control of the bleeding source; resection of contused, nonviable brain or intracerebral hematoma in select patients; and in some patients a decompressive craniotomy. This may be performed at the time of initial surgery or in a delayed fashion if further cerebral swelling develops. A chronic subdural hematoma may be removed through only a burrhole in many patients.
- **Prognosis:** Acute subdural hematoma usually are associated with underlying injury to the cerebral parenchyma and consequently the prognosis is poor. Patients who require a craniotomy for evacuation of subdural hematoma may not be able to participate further in collision or contact sports.

#### Extradural Hematoma !

Extradural hematomas are found in 10% of comatose TBI patients. They generally result from head impact in the temporal region that deforms or fractures the skull.

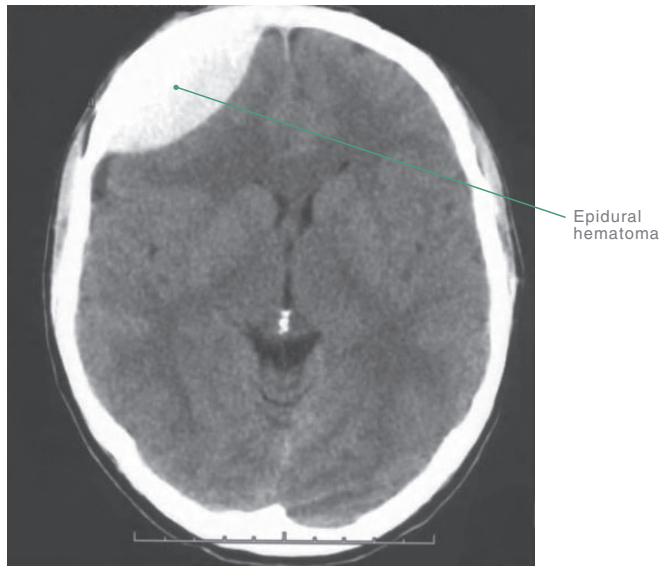


**Figure 4.4** Subdural hematoma with cerebral edema. Left-side subdural hematoma with air bubbles as a sign of skull fracture and torn dura, cerebral edema, and midline shift. (Reproduced with permission from the Norwegian Sports Medicine Association.)



The adherent dura is forcefully detached and hemorrhage occurs (Figure 4.5), arterial (the middle meningeal artery), venous, or both sources. Hemorrhage may also be seen under a fracture line in other regions of the skull. Injury to the brain under an extradural hematoma is rare.

- **Symptoms and signs:** Extradural hematomas may have a varied clinical presentation. The classic presentation is considered a loss of consciousness, recovery of consciousness (lucid interval) then a decline in consciousness. The presentation depends on the size and site of the hematoma, the rate of expansion, and the presence of associated intradural pathology. Extradural hematomas that involve the middle fossa (i.e., after temporal bone fracture) can cause precipitous decline in neurologic function since the mass effect has an early impact on the brainstem. In these patients contralateral weakness and ipsilateral pupil dilatation are common. Alteration in consciousness is the hallmark of extradural hematomas.
- **Diagnosis:** On brain CT scan acute extradural hematomas are hyperdense and lenticular or biconvex in shape.
- **Treatment:** Urgent neurosurgical consultation is required when an extradural hematoma is suspected. Rapid diagnosis and prompt surgical evacuation through a craniotomy are indicated when there are neurologic findings and depressed consciousness. Some surgeons advocate hematoma removal even in patients with only a headache when the blood clot is thicker than  $\geq 15$  mm or 30 ml in volume and associated with  $\geq 5$  mm of midline shift.
- **Prognosis:** When rapidly treated, the chances of a full functional recovery are excellent even in patients with profoundly abnormal neurological findings before surgery. Generally, patients who require a craniotomy for drainage of an extradural hematoma would not necessarily be precluded from further sports participation assuming full clinical and cognitive recovery.



**Figure 4.5** Epidural hematoma. (Reproduced with permission from the Norwegian Sports Medicine Association.)

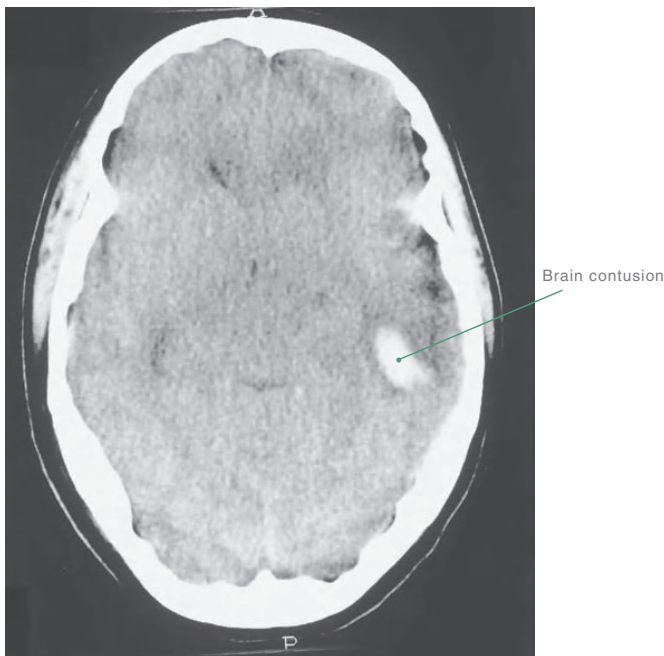
#### Traumatic Intracerebral Hematoma/Contusion !

Intracerebral hematomas and contusions are bleeding within the brain substance that appear as mass lesions. They may be divided into acute or delayed subtypes. Acute traumatic intracerebral hematoma occurs at the time of the initial head injury. Delayed traumatic intracerebral hematomas, which are more common, may develop in the hours or days (and even weeks) after initial injury particularly severe TBI. Brain tissue can be seen interspersed with hemorrhage on head CT scan in contusions but forms a coalesced hyperdense mass in an intracerebral hematoma on CT scan. Contusions are frequent in the frontal and temporal lobes since this tissue “slides” over the underlying rough bony surface of the skull base during acceleration/deceleration of the head. Contusions also may be seen under a depressed skull fracture. Penetrating head injury is also associated with intracerebral hematomas and contusions (Figure 4.6).

- **Symptoms and signs:** Intracerebral hematomas are more likely in more severe TBI but the clinical signs and symptoms depend on the size and location of the

intracerebral hematoma as well as the rapidity of its development. In many cases, there is a period of confusion or loss of consciousness but only one third of the patients remain lucid throughout their course. Impaired alertness and cognitive function are found frequently on initial examination. Focal findings are frequent and depend on lesion location.

- **Diagnosis:** In the acute phase, the diagnosis is usually made with a CT scan of the brain.
- **Treatment:** When this condition is suspected or diagnosed on imaging studies, an urgent neurosurgical consultation is required. Initial management is directed to control of ICP (see cerebral edema in the preceding text) and correction of any coagulation abnormalities. Intracerebral hematomas of >30 ml in volume, >3 cm in diameter, or associated with >5 mm of midline shift should be evacuated. However, the decision to operate depends on many factors, for example, hematoma location, patient age and coagulation status among others. For example, a 20 mL intracerebral hematoma in the temporal lobe may require surgical evacuation. The alert patient with a focal neurologic deficit and a small intracerebral hematoma (<3 cm) particularly those that are in a deep location can be observed closely. Occasionally an intracerebral hematoma may spread into the ventricles and cause intraventricular hemorrhage and hydrocephalus. These patients may benefit from a ventriculostomy. Patients with an intracerebral hematoma should receive seizure prophylaxis for 7 days unless seizures occur when a longer course is required. There is no role for corticosteroids.
- **Prognosis:** The overall recovery depends on what other injuries there are but when there is a small intracerebral hematoma in isolation, particularly in young individuals, recovery is generally good. However, overall mortality after traumatic intracerebral hematoma is about 30%. Patients who require a craniotomy for evacuation of intracerebral hematoma may not be able to participate further in collision or contact sports.



**Figure 4.6** Brain contusion. Left-side brain contusion in the temporal lobe, following a fall from a bicycle. (Reproduced with permission from the Norwegian Sports Medicine Association.)

#### Traumatic Subarachnoid Hemorrhage !

Subarachnoid hemorrhage often is found following severe or moderate head injury. Traumatic subarachnoid hemorrhage may occur in isolation but often occurs with other intracranial pathology, in particular subdural hematomas or intracerebral hematoma. In addition traumatic subarachnoid hemorrhage may result from blood vessel injury, for example, a vertebral artery dissection.

- **Symptoms and signs:** Subarachnoid hemorrhage typically presents with meningeal symptoms such as headache, neck stiffness and photophobia. The most common initial symptoms of vertebral artery injury causing subarachnoid hemorrhage are neck pain and occipital headache that may precede the onset of neurological symptoms. Traumatic subarachnoid hemorrhage usually is found in a diffuse pattern over the convexities and in the subarachnoid space. It is hyperdense on head

CT scan and unlike subarachnoid hemorrhage associated with a ruptured cerebral aneurysm is not usually observed in the basal cisterns.

- **Diagnosis:** When traumatic subarachnoid hemorrhage is suspected or diagnosed on imaging studies, an urgent neurosurgical consultation is required. Vascular imaging may be necessary to exclude a vascular injury particularly when there is penetrating injury or suspected vessel dissection that involves either the carotid or vertebral arteries.
- **Treatment:** There is no specific treatment of traumatic subarachnoid hemorrhage although there is some suggestion that calcium channel antagonists may be useful in some patients. Subarachnoid hemorrhage is associated with the development of vasospasm (delayed narrowing of cerebral vessels) that can contribute to delayed cerebral ischemia. These patients therefore require very careful fluid management. In addition, hydrocephalus may occur and require ventricular drainage or a shunt.
- **Prognosis:** The presence of traumatic subarachnoid hemorrhage is a factor associated with poor outcome after TBI. Patients who require a craniotomy for evacuation of hematoma or aneurysmal clipping may not be able to participate further in collision or contact sports.

#### Post-traumatic Epilepsy

Post-traumatic epilepsy may occur and is more common with increasing severity of brain injury and in particular intracranial pathology such as hemorrhage or a depressed skull fracture. A convulsing patient is at increased risk of hypoxia that can exacerbate the underlying brain injury. Airway management in these patients is important as is control of oxygenation and blood pressure. Management of post-traumatic seizures is determined by the timing of their occurrence in relation to the head injury. Since seizures may increase ICP or contribute to secondary brain injury, intense efforts should be made to prevent seizures during the recovery phase of the acute head injury. Prophylactic anticonvulsant medication is indicated when there is (1) an altered level of consciousness for a protracted time, (2) severe TBI (GCS  $\leq 8$ ), (3) focal lesions on CT, (4) depressed skull fractures, and (5) penetrating head trauma. Benzodiazepines (e.g., lorazepam, clonazepam, diazepam) can be used for the acute treatment of post-traumatic seizures, but they will produce at least transient impairment of consciousness. In the absence of a seizure, prophylactic medication can be stopped 7 days after injury since these medications do not prevent the development of post-traumatic epilepsy. If a patient develops further seizures, that is, post-traumatic epilepsy he or she should be managed in the same manner as symptomatic focal epilepsy from any etiology.

#### Post-traumatic Headache

Trauma to the head and neck in sport may lead to the development of headache. The initiating traumatic event may not necessarily be severe. The International Headache Society has published diagnostic criteria for post-traumatic headache and these include (a) the presence of significant head trauma as documented by loss of consciousness and/or post-traumatic amnesia  $>10$  minutes; (b) at least two abnormalities of the following: clinical examination, skull X-ray, neuroimaging, evoked potentials, CSF examination, vestibular function test, neuropsychological testing; (c) headache onset  $<14$  days post-trauma; and (d) the headache disappears within 8 weeks after trauma. There are a number of specific subtypes of post-traumatic headaches and these include post-traumatic migraine, extra-cranial vascular headache, and dysautonomic cephalalgia.

*Post-traumatic migraine* may resemble a typical migraine headache and is commonly seen in sports such as soccer, where repetitive heading of the ball gives rise to the term “footballer’s migraine.” One particular syndrome that is recognized in the setting of minor head blows is migrainous cortical blindness. This disturbing condition often raises fear of serious cerebral injury but tends to resolve over 1–2 hours. These are treated pharmacologically as for typical migraine. *Extracranial vascular headache* is periodic headaches at the site of head or scalp trauma. These headaches may share a number of migrainous features, although at times they can be described as “jabbing” pains. These are treated pharmacologically as for typical migraine. *Dysautonomic cephalgia* occurs in association with trauma to the anterior triangle of the neck, resulting in injury to the sympathetic fibers alongside the carotid artery. This results in autonomic symptoms such as Horner’s syndrome and excessive sweating associated with a unilateral headache. Propranolol has been used with some success in the management of this condition.

## Facial Injuries

*Per Skjelbred<sup>1</sup>, Glenn Maron<sup>2</sup>, and Robert Gassner<sup>3</sup>*

<sup>1</sup>*Oslo University Hospital, Oslo, Norway*

<sup>2</sup>*Emory University School of Medicine, Atlanta, GA, USA*

<sup>3</sup>*Medical University of Innsbruck, Maximilianstrasse, Innsbruck, Austria*


### Occurrence

Sport activities, traffic accidents, and violence are the three most prevalent causes of facial injuries. Injuries to the maxillofacial complex account for 3–29% of all sports-related injuries. Approximately 60–90% of these injuries occur in males between the ages of 10–29 years. The incidence of this type of injury varies and is difficult to establish due to the variety of environments and lack of reports. Facial injuries are caused by direct contact between athletes or sport equipment, such as hockey sticks, shoe spikes, goal posts, or railings. The shoulder and upper limb and the head of an opponent are the body parts that most frequently cause injuries to the face.

In amateur boxing, ice hockey, bandy, horseback riding, motorcycle sports, martial arts, and American football, mandatory protective equipment has indirectly reduced the number of facial injuries. Athletes in several sports wear mouthguards to prevent dental and orofacial injuries.

### Differential Diagnoses

Soft-tissue injuries including abrasions, lacerations and contusions are the most common sports-related maxillofacial injuries. In this setting, the practitioner must have a high suspicion for facial fractures and dental injuries. Often concomitant facial fractures accompany soft tissue injuries (see Table 4.6) and it is essential to arrange for appropriate clinical and radiographic investigations.

Most common	Less common	Must not be overlooked 
Grazes, p. 82	Tooth fractures, p. 86	"White eye syndrome", p. 89
Soft tissue contusions, p. 83	Soft-tissue loss, p. 87	Maxillary fracture, p. 90
Lacerations/cuts, p. 83	Intraoral soft-tissue injuries, p. 88	Retrobulbar hematoma, p. 90
Nasal fractures, p. 83	Frontal bone fracture, p. 88	Nasoorbitoethmoid fracture, p. 91
Mandibular fractures, p. 84	Orbital fracture, p. 89	Panfacial fractures, p. 91
Zygomatic fractures, p. 84	Alveolar ridge fracture, p. 92	Corneal erosion, p. 93
Tooth luxation, p. 86	Foreign object in the eye, p. 92	Contusion of the eyeball, p. 93
		Perforation of the eyeball, p. 94
		Septum hematoma

**Table 4.6** Overview of differential diagnoses for facial injuries. (Reproduced with permission from the Norwegian Sports Medicine Association.)

## Diagnostic Thinking

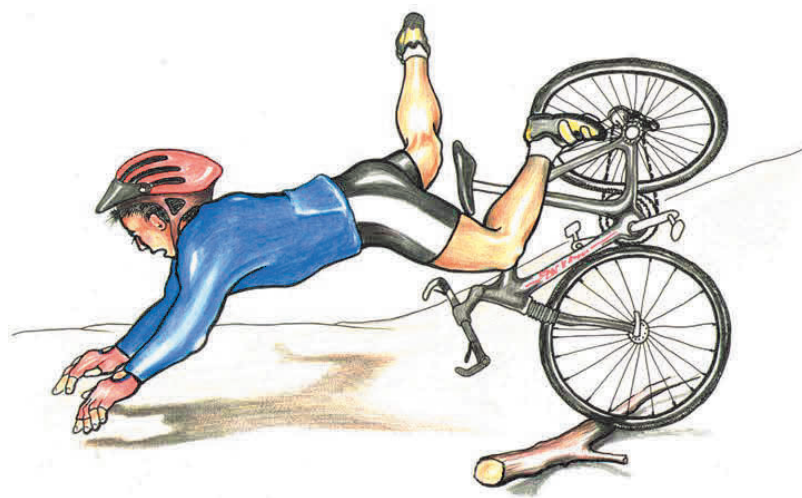
Sport-related facial injuries are seldom life threatening. However, the expanding use of new sport equipment, such as in-line skates, snowboards, and all-terrain bicycles, has increased the complexity of the injury pattern. The result is that primary caregivers are more frequently confronted with serious injuries. After the initial assessment of airways, breathing and circulation and an evaluation of cervical spine injuries, the examination of the maxillofacial complex may begin. If facial injuries are not treated properly, they may have functional or aesthetic sequelae. Referral to the appropriate specialist and thorough clinical examination is necessary to determine whether a patient with a facial injury needs to be sent for diagnostic imaging to exclude fractures.

If the patient has a severe facial injury, the airway may be obstructed by a foreign body, a blood clot, loose teeth, bone or a dislodged mouthguard. On-site treatment includes securing the airway and hemostasis. If this is difficult, the patient must be intubated. A cricothyrotomy may be necessary as an emergency procedure.

Direct pressure to a wound is a simple initial management of bleeding. It may be difficult to control bleeding from the throat, nose and mouth. Various methods, including nasal tamponade, an epistaxis catheter and compresses in the mouth may be used. Profuse facial bleeding may require intubation, epistaxis catheter, packing of throat and mouth with compresses, compresses over the face and circumfacial elastics to compress the entire maxillofacial complex. Imaging with angiography may be indicated followed by surgery or interventional radiography to control bleeding.

The goal of the clinical examination during the acute phase is to evaluate whether there is a soft-tissue injury or a more complex injury that requires treatment by a specialist. Patients with suspected fractures must be sent to the emergency room for imaging. A dentist must treat all patients with dentoalveolar injuries immediately. If the most important differential diagnoses can be excluded by means of a clinical evaluation, additional examinations for this purpose are unnecessary.

The injury mechanism is used as a basis for making the proper diagnosis and for determining the extent of the injury (see Figure 4.7). In most cases of facial injuries, the injured athlete is able to account for the injury mechanism. Most case histories



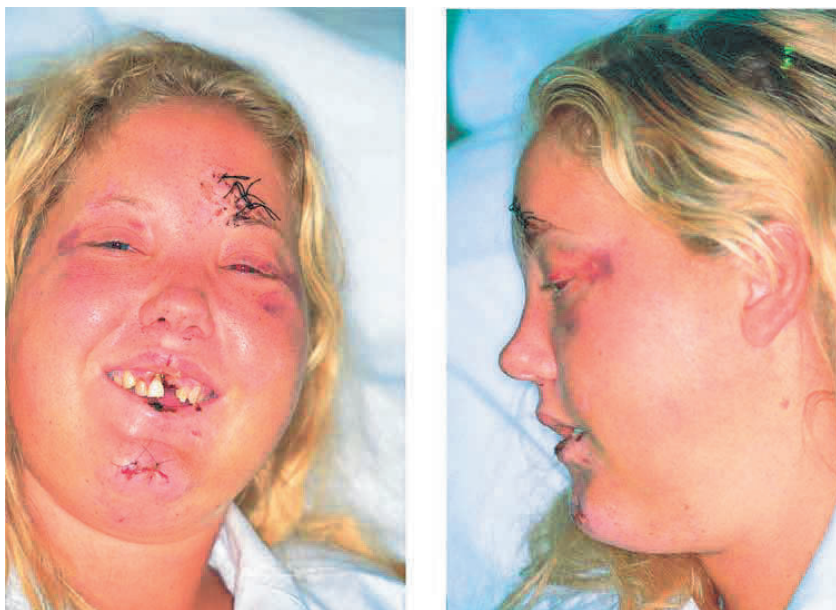**Figure 4.7** Injury mechanisms for facial injuries. Falls from bicycles often result in soft-tissue injuries, tooth injuries, and facial fractures. (© Medical Illustrator Tommy Bolic, Sweden.)

are one of two types: either the patient hit himself in the face or he got hit. The observations of fellow players may be important in making a proper diagnosis. Injuries to the oral cavity are often caused by direct trauma to the lips or teeth, caused by a blow or kick from an opposing player or by sport equipment, such as hockey stick, ice hockey puck, bandy ball or a ski pole.

### Clinical Examination

**Inspection.** The examination should take place as soon as possible after the injury. However, often the patient is not examined until several hours after the event. Swelling and pain may make the examination difficult. Double vision and/or occlusal bite changes are hallmarks of significant facial trauma. All wounds should be washed and cleaned. Then the patient's face is systematically examined. Depression fractures may be visible in the forehead. The bridge of the nose and the nasal septum are checked for deviation. Fractures in the nasoethmoidal area increase the distance between medial corners of the eyes (telecanthus), cause the tip of the nose to turn upward, and change the palpebral aperture (round doll's eye) on the affected side. A depressed zygomatic complex causes the contour of the cheekbone to become flattened. Injuries in the orbital area may cause changes in the position of the eyeball, such as proptosis (protrusion of the eyeball), hypophthalmos (inferiorly positioned eyeball) and enophthalmos (recessed eyeball), double vision, and reduced ocular movement. A depressed, elongated, widened midface indicates a fracture with dislocation (see Figure 4.8). Open bite often occurs. Malocclusion may be caused by fractures to both the upper and the lower jaw. Injuries to the lacrimal canal cause annoying tearing. Zygomatic arch fractures often interfere with jaw movement, hindering either opening or closure.

**Palpation.** If the patient has hematoma and a swollen face, thorough palpation of the underlying structures and the surrounding areas is necessary to exclude fractures in the area (see Figure 4.9). The facial skeleton is palpated for "depressions" or discontinuity. A depression in the middle lower section of the forehead, a loose nasal



**Figure 4.8** Midface fracture. Note that the midface is depressed and widened.

pyramid, and steps in the orbital margin are typical signs of fractures. In case of a zygomatic arch fracture, the arch may show a V-shaped depression between the zygoma and ear. Levels I–III Le Fort fractures cause the upper jaw or midface to be mobile. The temporomandibular joint spaces can be palpated, and an injury will usually cause pain here. In addition, the patient's mouth-opening range will be conspicuously reduced. Pathological movement when the lower jaw is bimanually palpated is an indication of fractures in the area. Irregularities in occlusion and in the dental arch are findings that require follow-up.

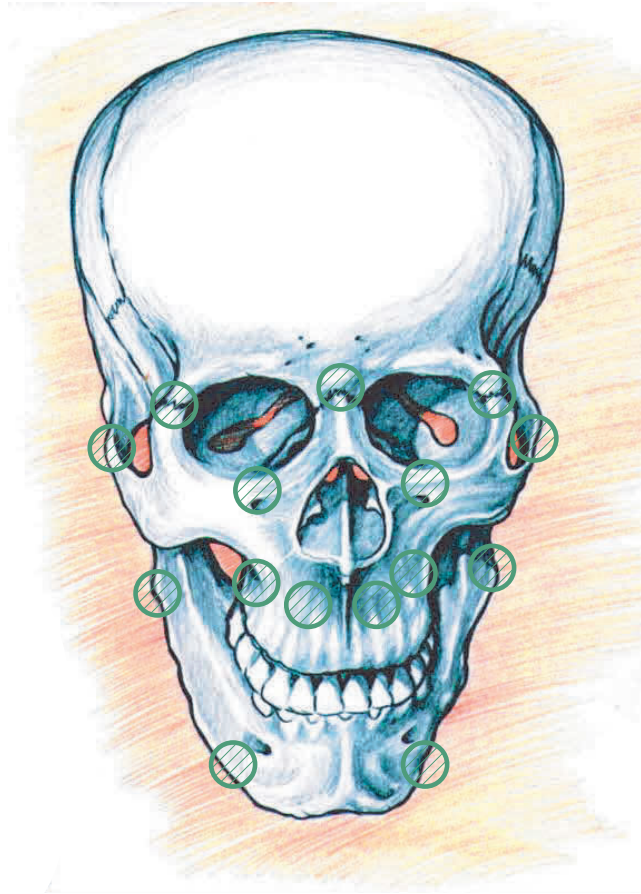
**Jaw movement.** The normal mouth-opening range of an adult is between 35 and 50 mm, measured between the incisive teeth in the upper and lower jaws.

The distance that the lower jaw can be moved forward varies from 2 to 6 mm in adults (measured in the area of the incisive teeth). Lateral movements range between 3 and 7 mm (measured in the canine-tooth region). If the patient has an acute injury, the mouth-opening range and the distance it can be moved forward and laterally may be conspicuously reduced. If there is a temporomandibular joint dislocation, the patient is unable to close the mouth. These dislocations also cause the lower jaw to deviate toward the contralateral side of the dislocation. Inability to open the mouth following an impact to the side of the head is often due to zygomatic arch trauma in a closed-mouth position, while inability to close an open mouth can be related to a broken zygomatic arch in an open-mouth position.

**Neuromuscular function.** Facial fractures can cause deficit in three sensory nerve branches of the trigeminal nerve. Injuries to the supraorbital nerve reduce sensation in the forehead. Injuries to the infraorbital nerve reduce sensation in the midface, whereas injuries to the inferior alveolar nerve and the mental nerve reduce feeling in the lower jaw and lower lip. Traumatic facial paresis rarely occurs in isolation although may be a complication of an underlying skull fracture. Deep facial cuts may cause damage to the nerve.

### Supplemental Examinations

**Radiographic examinations.** Plain radiographs for diagnosis of facial fractures are mostly limited to the nasal bone, mandible and teeth. An orthopantogram (OPG) can show mandibular fractures. If tooth fractures, tooth luxation, or fractures of the alveolar process are suspected, an OPG should be supplemented with dental X-rays. Nasal fractures are diagnosed using lateral X-rays, but decisions regarding the need



**Figure 4.9** Common midface fractures. Key palpation points are marked. (© Medical Illustrator Tommy Bolic, Sweden.)



for surgery on a nasal fracture depend on the clinical evaluation. Institutions that have DVT (digital volume tomography) devices can provide three-dimensional (3D) information based on dentofacial radiology. If fractures are found, additional CT scans are often indicated.

**CT scans.** CT scans with axial, coronal, sagittal and 3D images are mandatory if facial fractures are suspected, but should be ordered by a specialist, if possible. Coronal and sagittal images are necessary to demonstrate the extent of isolated orbital floor fractures. For Le Fort-type midface fractures, all possible types of CT scan projections (i.e., axial, coronal, and sagittal, as well as 3D reconstruction) should be used in the preoperative work, to obtain the best possible overview of the extent of the fractures. Newer CT machines may completely replace conventional radiographic examinations, because both OPG and dental X-rays are possible.

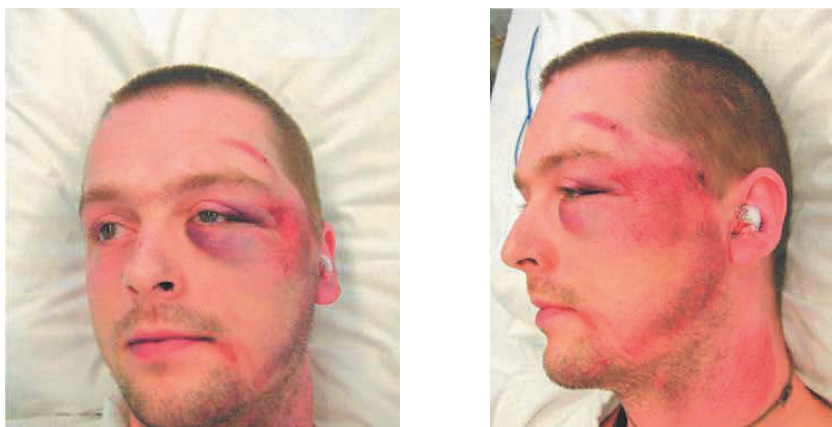**MRI.** An MRI is not used for standard facial injury examinations. It may however, provide useful information about injuries to the eye and the surrounding soft tissue as well as in evaluation of temporomandibular joint trauma.

## Specific Diagnoses—Common Injuries

### Grazes

Grazes occur frequently.

- **Symptoms and signs:** Superficial wounds limited to the epidermis and dermis are caused by falls on a rough surface (see Figure 4.10).
- **Diagnosis:** The diagnosis is made clinically by inspection (and palpation) of the injured area after dirt has been removed.
- **Treatment by physician:** Abrasions are partial damage to the skin. Abrasions heal by re-epithelialization. Wounds that are penetrated by dirt particles often heal with permanent tattooing if the particles are not removed. If the graze has much dirt, cleaning is a painful procedure, and sometimes it must be done under general anesthesia.
- **Prognosis:** Healing is usually uncomplicated if the wound is protected by a thin layer of antibiotic ointment and cleaned daily, to remove exudative residue. Occlusive dressings have been shown to improve healing of skin lesions rather than the traditional approach of open or “dry” wound dressing.



**Figure 4.10** Abrasion. Facial grazes after falling while rollerblading.

### Soft Tissue Contusions

Blows and pinching injuries are among the most frequent soft-tissue injuries in sport.

- **Symptoms and signs:** Ruptures of small veins, with bleeding in the skin, cause redness and variable degrees of hematoma formation in the affected area.
- **Diagnosis:** The diagnosis is made clinically by inspection and palpation of the injured area, after dirt has been removed.
- **Treatment by physician:** After underlying fractures have been excluded, the most important task is to reduce inflammatory reactions. Elevation of the head and ice packs during the first 2–4 hours will counteract swelling and discomfort. After 48 hours, the acute inflammatory phase begins to subside. Paracetamol and glucocorticoids have been documented to reduce swelling and pain in the facial area.
- **Prognosis:** Most contusion injuries require no further treatment after 48 hours and heal spontaneously in 1–2 weeks.

### Lacerations/Cuts

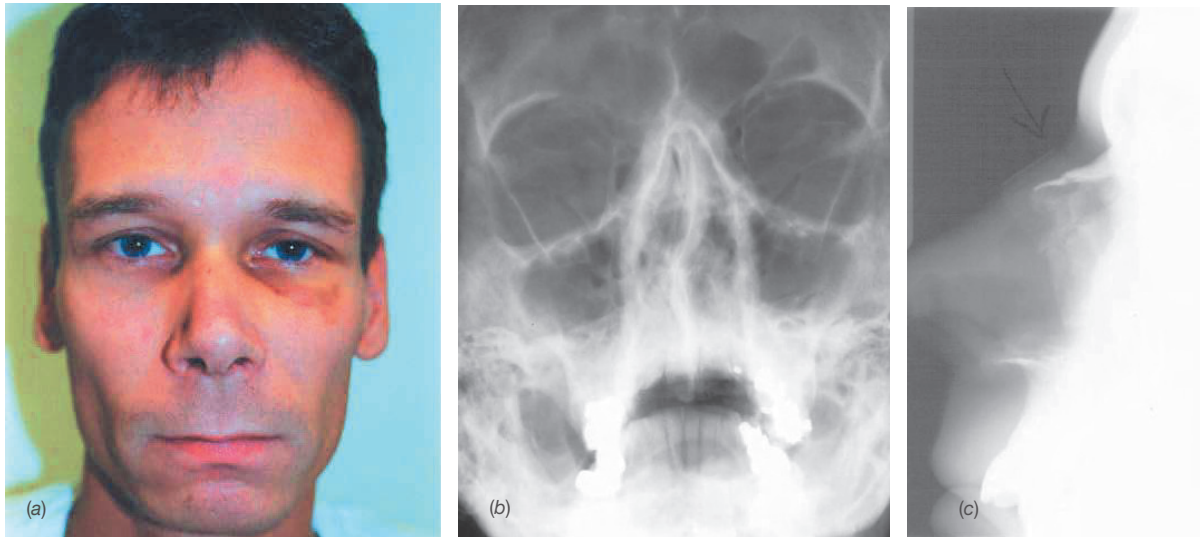
Cuts include tears and puncture wounds that are often caused by sport equipment penetrating the skin. For example, cuts are often caused by knobs on soccer shoes, spiked shoes, and sharp edges on ski equipment.

- **Symptoms and signs:** Less complicated cuts and punctures are usually superficial.
- **Diagnosis:** If the wound is deep, a neurological examination must be performed, so that nerve damage can be ruled out.
- **Treatment by physician:** Superficial tears and puncture wounds are treated with skin sutures and taping. The use of 5.0 sutures is recommended.
- **Prognosis:** The patient must be informed that it takes several months before facial scars are finally mature. Martial arts practitioners, in particular, must be informed that resuming the sport too soon after the injury may lead to complications during the healing period. For the first 6 months, scars must be protected from the sun by applying sun block or bandages to prevent hyperpigmentation.

### Nasal Fractures

Fractures of the nasal skeleton are among the most frequent types of sport injuries to the face:

- **Symptoms and signs:** Symptoms and signs of nasal fractures are malalignment of the nasal skeleton, hematoma, and soft-tissue swelling.
- **Diagnosis:** For a proper diagnosis, the practitioner must evaluate the following: blows to the nasal area, mobility and crepitation of the nasal skeleton, bleeding, swelling, hematoma, and reduced airflow in the nose. Nasal fractures are diagnosed radiographically, using lateral images, but the need to surgically treat a nasal injury depends on the clinical evaluation (see Figures 4.11a, 4.11b, 4.11c).
- **Treatment by physician:** The patient should be referred to an ear, nose, and throat specialist. Septum hematoma must be evacuated. Closed nasal bone reposition is the most common treatment. This should be done either immediately after the injury or 3–7 days later, when the swelling is reduced.
- **Prognosis:** The prognosis is good. The patient should wear a protective splint or face mask for 4 weeks when participating in training or competition.

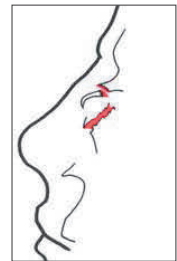

**Figure 4.11** Nasal fracture with deviation of the bridge of the nose. The sagittal view shows a nasal bone fracture (a). The frontal view demonstrates traumatic septum deviation (b). Nasal fracture with deviation (c).

#### Mandibular Fractures

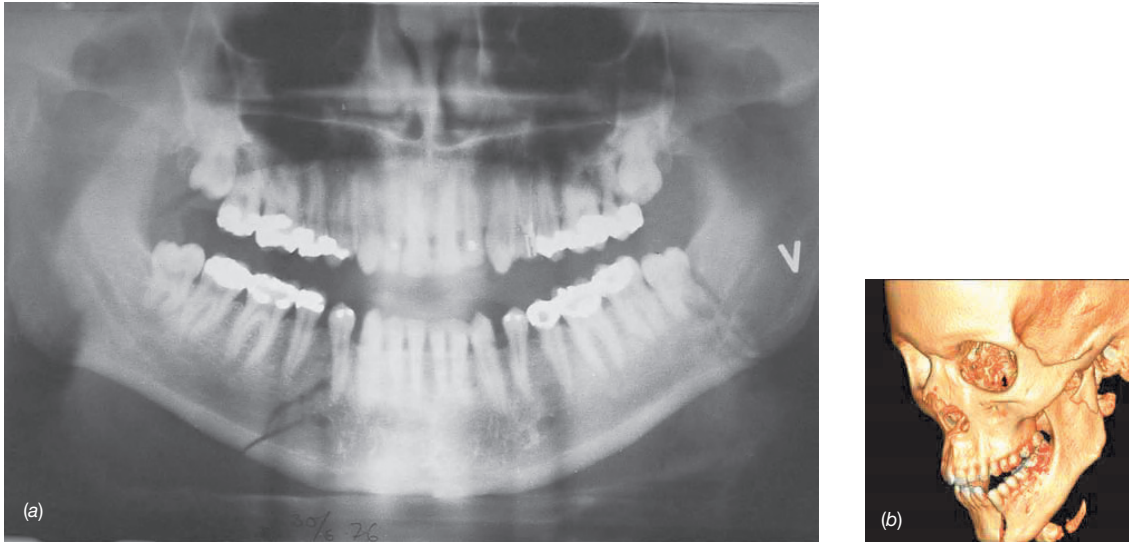
Mandibular fractures are the second most common group (13–45%) of sport-related facial injuries. They are usually caused by a blow to the lower jaw, such as may occur in fighting and team sports. Falls in which the lower jaw or the chin hits a hard surface are another common injury mechanism.

- **Symptoms and signs:** Symptoms and signs of mandibular fractures are malocclusion, pathological mobility and anesthesia of the inferior alveolar nerve. Fractures of the joint may cause laceration and bleeding from the ears.
- **Diagnosis:** Definite signs of a fracture are changes in occlusion and mobility in the area of the fracture. The standard radiographic examination is an OPG (see Figures 4.12a and 4.12b) or CT scans. Fractures of the joint causes deviation of the chin when opening the mouth.
- **Treatment by physician:** Most mandibular fractures should be treated by a specialist. To achieve proper occlusion, the fractured fragments must be anatomically reduced and then fixed using mini titanium plates. Mandibular fixation is always used intraoperatively but is seldom needed after surgery. Soft food is recommended for 4 weeks. Temporomandibular joint fractures with fracture lines in the joint area are difficult to operate on and are treated conservatively with intermaxillary fixation for 3–6 weeks.
- **Prognosis:** The prognosis depends on the extent and the location of the fracture. If proper occlusion is achieved after the operation, the prognosis is good. Fractures in the joint may cause permanent malocclusion and reduced mouth opening ability.



#### Zygomatic Fracture

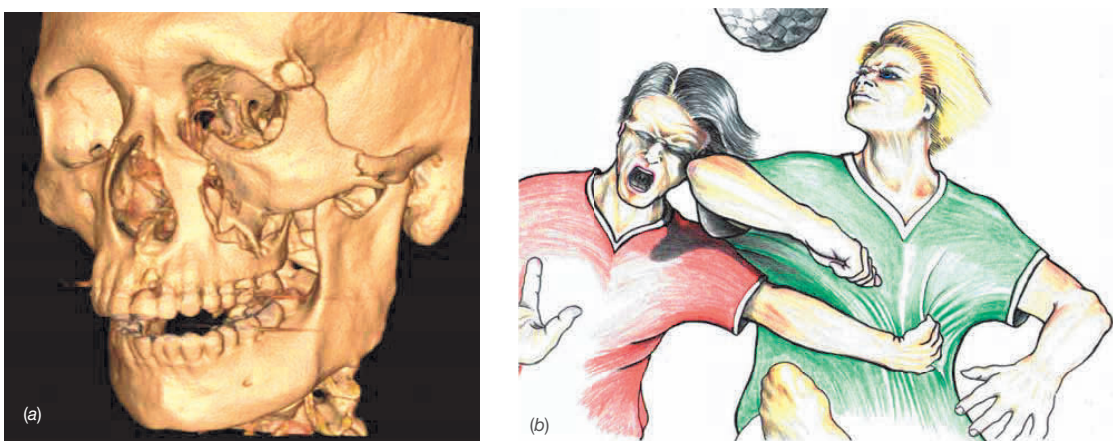
Typical cheekbone fractures involve fractures in the suture lines between the zygoma and the adjacent bones (sphenoid, frontal, maxilla, and temporal bone) (see Figures 4.13a and 4.13b). Cheekbone fractures are the third most common sport



**Figure 4.12** Mandibular fracture. The orthopantomogram (OPG) demonstrates a right-side subcondylar fracture, a right-side angulus fracture, and a left-side body fracture (a). The three-dimensional reconstructed CT image illustrates a paramedial mandibular fracture and a subcondylar fracture (b). (Reproduced with permission from the Norwegian Sports Medicine Association.)

injury to the face. In case of an impending injury, the athlete will often turn the head to the side, making the cheekbone more vulnerable to injury.

- **Symptoms and signs:** The clinical presentation of a cheekbone fracture is a flattening of the prominence of the cheekbone. If the cheekbone is pressed inward, it may be difficult for the patient to open the mouth wide. Double vision and nerve injury corresponding to the infraorbital nerve are symptoms of a fracture in the orbital floor. Isolated fractures of the zygomatic arch can be palpated.



**Figure 4.13** Zygomatic fracture. Dislocated left-side zygomatic fracture (a). A common injury mechanism is trauma to the cheekbone (b). (© Medical Illustrator Tommy Bolic, Sweden.)

- **Diagnosis:** Dislocations and broken edges that can be palpated on the infraorbital rim, the intraoral zygomaticomaxillary buttresses, and the lateral orbital rim are definite signs of a fracture. A CT scan (with axial and coronal views) provides the best imaging.
- **Treatment by physician:** Treatment consists of open reposition and plate osteosynthesis. If the lateral orbital floor is fractured, the herniated orbital content is reduced and the orbital floor is reconstructed. A facial injury specialist should treat these injuries.
- **Prognosis:** The extent of the fracture and the possibility for surgery immediately after the injury determine the result. Secondary corrections are generally considered difficult, as they require a more extensive approach for reconstruction with several osteotomies prior to reduction and refixation.

### Tooth Luxation

Tooth luxations (dislocations) are divided into subtotal and total luxations. Subluxation often occurs when the alveolus is fractured, causing the tooth to be luxated out of normal position. Total luxation is complete avulsion of the tooth. In these cases the alveolus is often without fractures.

- **Symptoms and signs:** The tooth is subluxated or completely knocked out of the alveolus.
- **Diagnosis:** Diagnosis is made through a clinical examination.
- **Treatment by dentist:** The treatment of subtotal luxations consists of reposition in the proper anatomic position and fixation with the help of an arch bar. The fixation period is 4 weeks. For total luxation, vital tissue on the root surface must be treated carefully. The outcome of the treatment depends on how long the tooth is outside the alveolus and in which medium it is stored. Ideally, the tooth should be put back in the alveolus immediately and held in place with the patient's mouthguard or a foil splint until an urgent dental consultation is achieved. The ultimate prognosis of tooth replantation depends upon its time out of the mouth. In general, once a tooth has been out for more than 20 minutes, the chances of a successful replantation are reduced substantially.

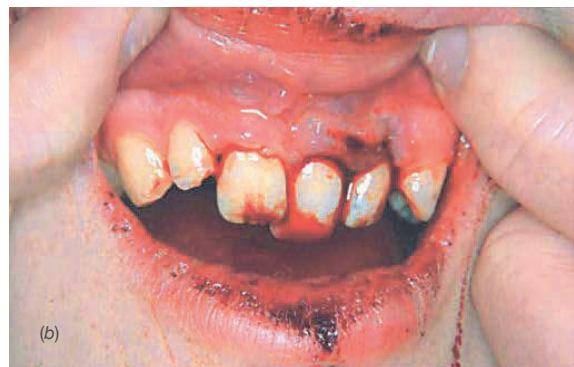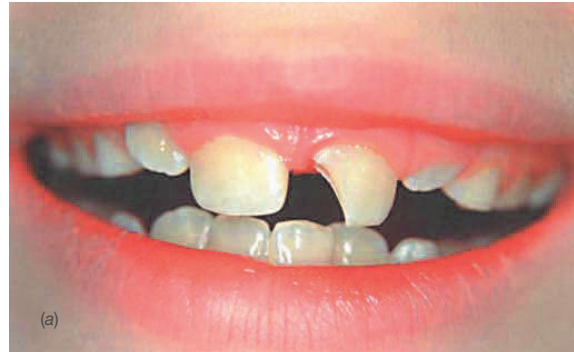If the tooth is contaminated, it should be carefully cleaned in sterile saline. It must not be scrubbed as the periodontal cells critical for healing may be damaged. The best temporary storage media are sterile saline, saliva or milk. The tooth is replanted as quickly as possible and fixed using an arch bar for 1–2 weeks, if the alveolus is intact. In case of total luxations and alveolar fractures, fixation time is 4 weeks. Prophylactic antibiotic treatment is recommended.

- **Prognosis:** Teeth that have not completed root growth may be revitalized. If root growth is complete, root canal treatment should be undertaken 7–10 days after luxation. Even after successful replantation the root may be resorbed after some time. While replantation of permanent frontal teeth should be the prime goal in children and adolescents due to facial growth patterns, a dental implant should always be considered as an alternative to replantation in adults.

### Tooth Fracture

Tooth fractures are divided into crown fractures and root fractures (see Figures 4.14a and 4.14b).

- **Symptoms and signs:** Crown fractures may occur without or with pulp exposure. If the crown of the tooth is bleeding, the pulp is exposed. Malalignment of the entire crown of the tooth is another sign.
- **Diagnosis:** Diagnosis is made by clinical examination and (radiography) dental X-rays.
- **Treatment by dentist:** Normally, crown fractures are reconstructed with dental materials. If the pulp is open, root canal filling is usually necessary. In children, however, because the growth of the root of the tooth is not complete, only the upper portion of the pulp is removed. Split or longitudinal fractures result in extraction of the tooth. Root fractures are treated by exact repositioning of the crown of the tooth using a stable arch bar. The brace should be worn for 2–3 months.
- **Prognosis:** The esthetic result is often very good for crown fractures without opening of the pulp. Pulp opening and subsequent root filling may cause varying degrees of discoloration of the tooth. The prognosis for root fractures is good if the fracture ends are slightly displaced. If dislocation of the crown fragments is substantial, fracture healing is not very likely. Root filling of these teeth must be done early.



HEAD AND FACE

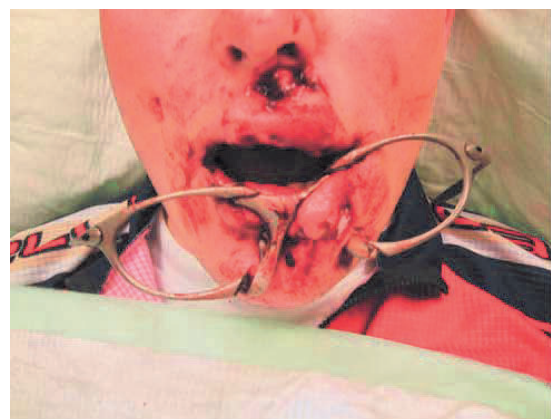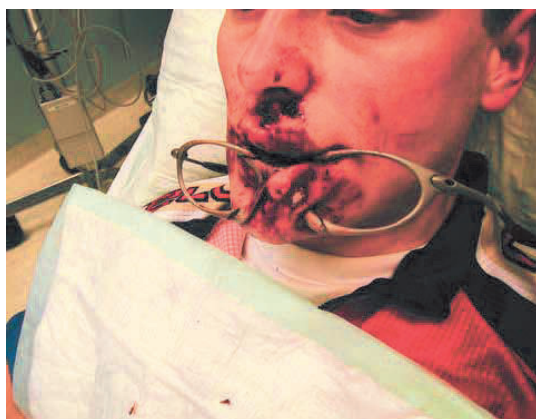### Other Specific Diagnoses

#### Soft-Tissue Loss

Extensive facial injuries with tissue loss are rare in sport. They occasionally occur as a result of horseback riding, skiing, and bicycling accidents (see Figures 4.15).

- **Symptoms and signs:** Extensive soft-tissue injuries are often combinations of lacerations, abrasions, and contusions.

**Figure 4.14** Crown and root fractures. Crown fracture with exposed pulp (a). Root fracture with a dislocated crown fragment (b). (Reproduced with permission from the Norwegian Sports Medicine Association.)



**Figure 4.15** Soft-tissue injury. A bicyclist who got his own glasses stuck in his lower lip. (Reproduced with permission from the Norwegian Sports Medicine Association.)

- **Diagnosis:** Initially, this type of injury is examined carefully after a thorough cleaning. If palpation indicates an injury to the underlying bone structure, the athlete must be sent for radiographic clarification. The trigeminal nerve and facial nerve must be tested for skin sensation and motor innervation.
- **Treatment by physician:** Debridement must be conservative for star-shaped wounds, so that enough tissue is kept to allow closing, thus preventing displacement of neighboring structures. Major defects require plastic reconstructive techniques.
- **Prognosis:** This treatment often has a surprisingly good outcome, with few disfiguring scars.

#### Intraoral Soft-tissue Injuries—*Soft-tissue Injuries in the Oral Cavity*

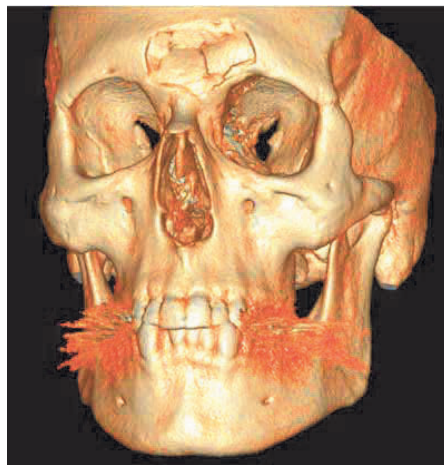
The most frequent injuries occur to the lips and the anterior part of the mucous membrane of the mouth. Injuries to the buccal mucosa and to the palate are rare:

- **Symptoms and signs:** Symptoms and signs are bleeding from the oral cavity and lips and, frequently, hematoma and swelling shortly after the injury occurs.
- **Diagnosis:** The physician must thoroughly inspect and palpate the injured area. This requires good light and suction.
- **Treatment by physician:** The principles that apply for extraoral soft-tissue injuries also apply for intraoral injuries. The use of ointments and bandages is unnecessary. Suturing with 3.0 resorbable sutures is recommended. In the lip area, single 5.0 nonresorbable sutures are recommended. Precise suturing of the red-white lip line is key. The sutures are removed after 7 days. Good oral hygiene is maintained by rinsing with chlorhexidine gluconate, because it may be difficult for the patient to brush the teeth.
- **Prognosis:** Normally, wounds in the oral cavity heal without complications.

#### Frontal Bone Fracture

Fractures of the forehead are often caused by a blow to the lower portion of the forehead and are typically the result of (being kicked by a horse or of) head duels in soccer. These fractures are rare: They represent only 2% of sport-related injuries to the face.

- **Symptoms and signs:** Visible or palpable depressions in the area above the frontal sinus indicate frontal bone fracture (see Figure 4.16).
- **Diagnosis:** A definite sign of a fracture is a palpable depression with crepitation in the anterior wall of the frontal sinus. Sensory deficit in the area of innervation of the supraorbital nerve is also considered a sign of a fracture in this area. To exclude a frontobasal injury, the doctor must always order a CT scan.
- **Treatment by physician:** Fractures with depression of the anterior wall of the frontal sinus may cause



**Figure 4.16** The three-dimensional reconstructed CT image illustrates an impression fracture of the forehead. (Reproduced with permission from the Norwegian Sports Medicine Association.)

aesthetic and functional sinus problems. Surgery is often recommended. If there are fractures of both the anterior and the posterior wall of the frontal sinus, with air intracranially and liquorrhea as signs of dura damage, further treatment must be given, in collaboration with a neurosurgeon.

- **Prognosis:** The prognosis is good. For larger injuries, the prognosis depends on additional intracranial injuries.

#### Orbital Fracture—Eye Socket Fracture

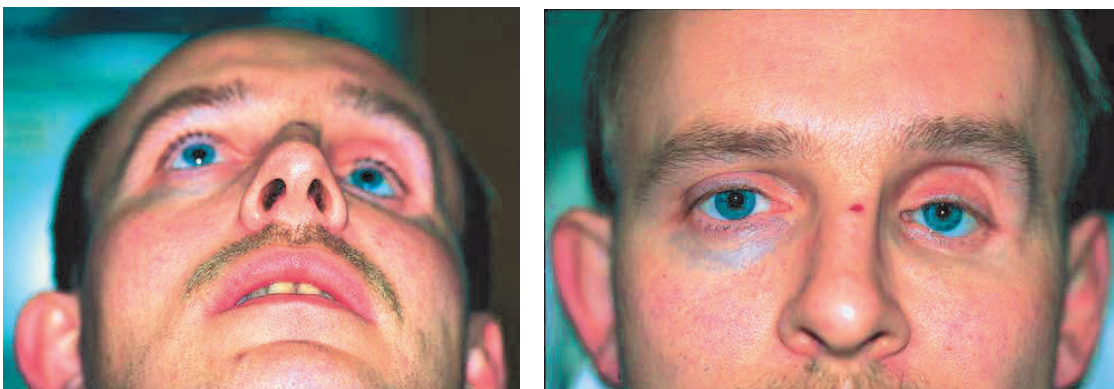
Fractures of the orbit includes the floor, medial wall, roof and lateral wall. Lateral wall dislocation indicates that there is a zygomatic fracture. Roof fractures are seen in frontal fractures. Blunt trauma to the orbital region results in fractures of the floor and medial wall (blow-out fractures). Blow-out fractures are among the least common sport injuries. The classic causes are tennis or squash balls hitting the eye. The most common orbital floor fractures seen are those caused by running into elbows or fists during team sports. Fractures of the infraorbital rim are a relatively common result of this type of injury:

- **Symptoms and signs:** Findings that indicate fractures are periorbital swelling, monocular hematomas, lateral subconjunctival bleeding, recessed eyeball (enophthalmos), inferiorly positioned eyeball (hypophthalmos), sensory deficit in the area of the infraorbital nerve, limited ocular movements, and double vision.
- **Diagnosis:** A CT scan of the orbit with coronal, axial and sagittal sections provides a good overview of fractures in the orbit (see Figure 4.17).
- **Treatment by physician:** Indications for surgical intervention are mainly diplopia caused by enlargement of the orbit with hypophthalmos and enophthalmos.
- **Prognosis:** The extent of the fracture and the possibility of surgery immediately after the injury determine the outcome. Secondary corrections are often difficult, and the results are not as good as they are for immediate surgery.

#### “The White Eye Syndrome” !

In young persons, trauma to the orbital region may cause a green-stick fracture in the floor that traps the inferior rectus muscle:

- **Symptoms and signs:** Upward rotation of the eye is restricted (Figure 4.18).



**Figure 4.17** Orbital fracture with enophthalmos and hypophthalmos. Injury to the orbital floor may lower the position of the bulb, whereas fractures in the floor and walls increase the volume of the orbit and causes a recessed eyeball. (Reproduced with permission from the Norwegian Sports Medicine Association.)



- **Diagnosis:** Diagnosis is based on recent trauma and restricted upward rotation. CT is not necessary and delays treatment.
- **Treatment by physician:** This is an emergency that needs surgical intervention within 24 hours to avoid permanent damage to the muscle.

**Retrobulbar Hematoma !**

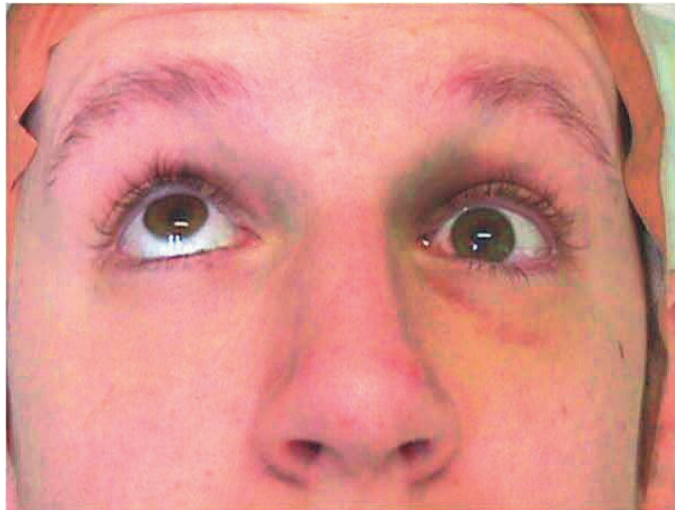Trauma to the orbital region may cause retrobulbar bleeding (Figure 4.19). This may cause an orbital compartment syndrome that affects circulation and nerve function:

- **Symptoms and signs:** Elevated, protruded, red eye. Gradual loss of vision and eye movement (the ability to move the eye).
- **Diagnosis:** A history of trauma and the findings described in the preceding text is sufficient for diagnosis. CT or MRI scans may verify the diagnosis, but valuable time is lost.
- **Treatment by physician:** A lateral canthotomy should be performed as fast as possible to save vision. This procedure can be done in local anesthesia.

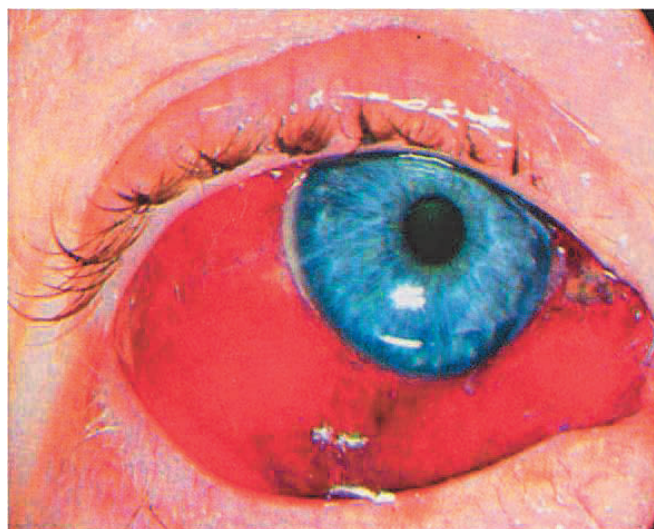
**Maxillary Fracture—Midface Fracture !**

Maxillary fractures result from trauma to the midface. The result is a loosening of (1) the upper jaw (Le Fort I); (2) the upper jaw with the nasal bone (Le Fort II); or (3) the entire midface with the upper jaw, cheekbone, and nasal bones (Le Fort III) (see Figure 4.20). Sport-related Le Fort fractures are rare and make up only 1–3% of all sport injuries to the face. The most common injury mechanisms are falls from great heights, high-speed trauma, winter sport trauma, and bicycling and climbing accidents:

- **Symptoms and signs:** Malocclusion combined with (problems involving mobility of the upper jaw or the central or entire midface and bleeding are characteristics of all Le Fort fractures. Typical symptoms are periorbital hematoma (raccoon eyes), rhinorrhea, and backward and downward dislocation of the midface (dish face) with anterior open bite.
- **Diagnosis:** Definite signs of fracture are changes in occlusion combined with mobility in the upper jaw or midface. A CT scan provides the best overview.



**Figure 4.18** Youth with white eye syndrome after trampoline accident. (Reproduced with permission from the Norwegian Sports Medicine Association.)



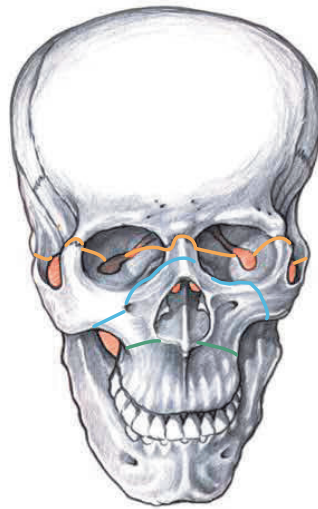**Figure 4.19** Retrobulbar hematoma. (Reproduced with permission from the Norwegian Sports Medicine Association.)

- **Treatment by physician:** Maxillary injuries should be treated by a facial injury specialist. Dislocated fragments are reduced and fixed using titanium plates.
- **Prognosis:** The extent of the fracture and the possibility for surgical intervention immediately after the injury determine the result. Secondary corrections are difficult to make, and the results are not as good as the results of immediate correction.

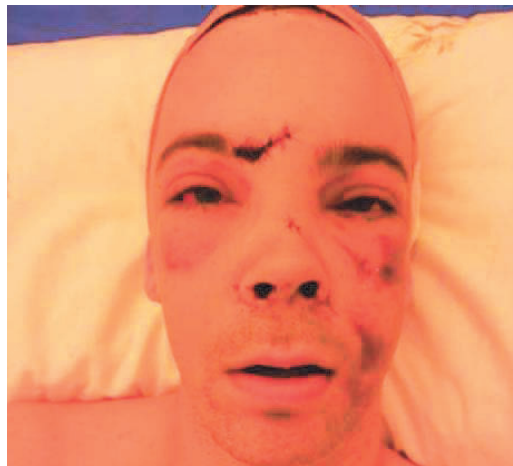#### Nasoorbitoethmoid Fracture—Combined Nose and Lacrimal Bone Fractures !

Nasoorbitoethmoid fractures are localized to the area between the eyes, consisting of the nasal bone (and), the frontal process of maxilla, the lacrimal bone and the ethmoid bone. (see Figure 4.21). These bones are thin and fracture easily. Therefore, parts of the nasal complex can be pushed posteriorly and laterally. This may cause damage to the lacrimal canal and the medial attachment of the eyelids (canthal ligament). The medial attachment of the eyelids may become loose and displaced laterally.

- **Symptoms and signs:** Symptoms and signs include the depressed bridge of the nose, an increased distance between the medial canthi (telecanthus), a changed palpebral aperture (doll's eye), and a turned-up apex of the nose.
- **Diagnosis:** Diagnosis is made using a CT scan and is indicated by an increased distance between the canthi combined with a fractures in the area.
- **Treatment by physician:** A specialist in facial injuries should treat this type of injury.
- **Prognosis:** The prognosis depends on the complexity of the fracture. A good outcome depends on surgery immediately after the injury occurs, with exact repositioning of the bone fragments and canthal ligaments (canthopexy). Secondary corrections are very difficult, and the results are not as good as the results of immediate correction.



**Figure 4.20** Le Fort I–III fractures. The most common fracture lines in the midface. (© Medical Illustrator Tommy Bolic, Sweden.)



**Figure 4.21** Nasoorbitoethmoid fracture. The typically depressed root of the nose, turned up apex and telecanthus.

#### Panfacial Fractures—Multiple Fractures in the Facial Skeleton !

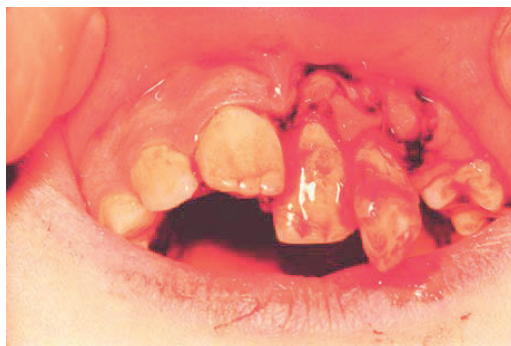Panfacial fractures are caused by major trauma to the face. They include multiple fractures in the facial skeleton (i.e., the forehead, cheekbone, nose, upper jaw, and lower jaw):

- **Symptoms and signs:** Symptoms and signs are total crushing of the face, with pathological movement of the fragments; and flattened, widened, and lengthened midface, combined with occlusion problems.
- **Diagnosis:** Clinical examination and CT scan.
- **Treatment by physician:** A facial injury specialist must treat this type of fracture. Extensive exposure of the facial skeleton combined with careful repositioning and plate fixation in a given sequence is required. Lost bone is replaced with calvary bone grafts.
- **Prognosis:** Prognosis is good when the fragments are properly reduced.

#### Alveolar Ridge Fracture

Alveolar ridge fractures are segment jaw fractures with two or more teeth (see Figure 4.22):

- **Symptoms and signs:** Symptoms and signs are abnormal mobility of the tooth segment, changes in occlusion, differences in the level of the tooth row, bleeding, and injuries to the mucous membrane.
- **Diagnosis:** The diagnosis is made radiologically, with OPG and dental X-rays; and clinically, by mobility of the tooth segment.
- **Treatment by physician:** The physician performs repositioning and fixation of the fractured fragment with the help of arch bars. The bars are used for 4 weeks. If insufficient stability is achieved using labial arches, the patient must have intermaxillary fixation for a few weeks. Open reposition using plates may cause healing problems in the form of poor circulation to the reduced fragments and is seldom used.
- **Prognosis:** The result depends on reduction of the injured fragments. If this is done correctly, permanent changes in bite are avoided. A dentist must evaluate the teeth with respect to the need for root canal treatment.



**Figure 4.22** Alveolar ridge fracture. Fracture of the tooth alveolus with subluxation of the teeth. (Reproduced with permission from the Norwegian Sports Medicine Association.)

#### Foreign Object in the Eye

Specks of dust often get stuck in the tarsal sulcus on the inside of the upper eyelid.

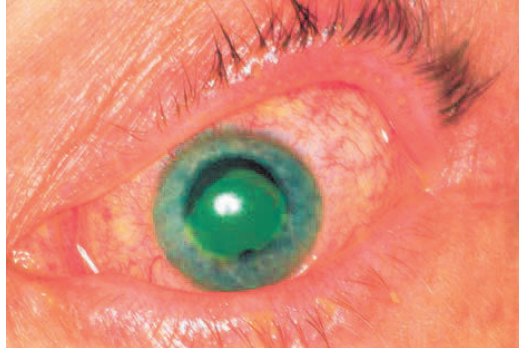
Blinking is painful and may cause epithelium damage on the cornea:

- **Symptoms and signs:** Symptoms and signs are pain, red eye, and tearing.
- **Diagnosis:** The foreign object is visible when the eyelid is examined by turning it inside out.
- **Treatment by physician:** Foreign objects are removed, possibly after anesthetization with oxybuprocaine eye drops. Antibiotic ointment for 3 or 4 days is recommended as an infection prophylactic.

**Corneal Erosion !**

Contact with branches, fingernails, or other objects often cause wounds on the cornea (see Figure 4.23):

- **Symptoms and signs:** Strong pain, tearing, eyelid cramps (blepharospasm), sensitivity to light, and blurred vision are symptoms and signs of corneal erosion.
- **Diagnosis:** Diagnosis is made by fluorescein solution, which colors erosion.
- **Treatment by physician:** Local antibiotics, such as chloramphenicol ointment overnight, and perioral analgesics are used. Diclofenac eye drops may be tried.
- **Prognosis:** In most cases, healing occurs within 24 hours.

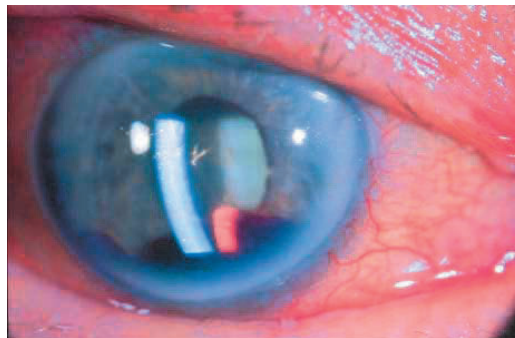

**Figure 4.23** Corneal erosion. Fluorescein-colored corneal erosion. (Reproduced with permission from the Norwegian Sports Medicine Association.)

**Contusion of the Eyeball !**

Contusion of the eyeball (see Figure 4.24) may be caused by direct blows to the eye (boxing), a ball in the eye (squash), crashing into a hard object, and falling accidents.

- **Symptoms and signs:** Tearing, light sensitivity, and blepharospasm (cramps of the eyelid) are signs and symptoms of contusion of the eyeball.
- **Diagnosis:** Diagnosis is made if any of the following have occurred: swelling and bleeding in the eyelid, subconjunctival bleeding, corneal edema, corneal damage, bleeding in the anterior chamber (hyphema), separation of the iris (iridodialysis), traumatic paresis of the pupil (mydriasis, oval pupil), accommodation paresis, lens damage or dislocation, bleeding in the vitreous, retinal damage (bleeding or edema), or damage to the optic nerve.
- **Treatment by physician:** The physician should examine the eye while it is under surface anesthesia, and refer the patient to an ophthalmologist. Blunt trauma to the eyeball may have serious consequences. The diagnosis may be difficult to make, because several areas of the eye may be injured. For this reason, the threshold for referral to an ophthalmologist should be low.
- **Prognosis:** Prognosis depends on the extent of the injury and the possibility of treatment by an ophthalmologist.



**Figure 4.24** Contusion of the eyeball. Bleeding in the anterior chamber and the iris. (Reproduced with permission from the Norwegian Sports Medicine Association.)

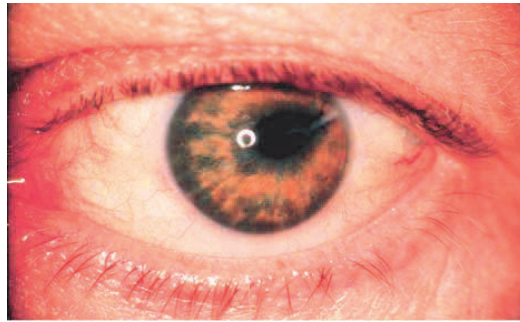
**Perforation of the Eyeball** !

Ski poles in the eye, bow and arrow shooting accidents, and accidents with other sharp objects frequently cause eye perforation (see Figure 4.25). Ruptures of the eye may also be caused by powerful blunt contusion trauma. In that case, the eye ruptures at the weak points (along the limbus and the optic nerve):

- **Symptoms and signs:** The case history is crucial. Perforation may be difficult to see. If perforation is suspected, the patient should be sent to the nearest ophthalmology department.

The parenteral use of an antibiotic prophylactic (e.g., benzylpenicillin) may be necessary if transport will take a long time. It is critical that the patient avoids straining or coughing otherwise extrusion of the intraocular contents may result. Consideration of the use of a parenteral antiemetic during transport is recommended.

- **Diagnosis:** A specialist confirms the diagnosis.
- **Treatment by physician:** Treatment of a perforated eyeball must be done by a specialist.
- **Prognosis:** Prognosis depends on the extent of the injury.



**Figure 4.25** Perforation of the eyeball. Perforated eye that is not circular. Contusion changes of the pupil. (Reproduced with permission from the Norwegian Sports Medicine Association.)